

JUVENILE DIFFUSE LARYNGEAL PAPILLOMATOSIS: CASE REPORT

Burgio A., *Vessio G., Varetti C., Fanti F., Bulotta Al., Meucci D., Pavone M., Messina M.

Division of Pediatric Surgery, Department of Pediatrics,
Obstetrics and Reproductive Medicine, University Of Siena

*Department of Otolaryngology, University of Siena, School of Medicine, Siena, Italy.

Introduction. Juvenile laryngeal papillomatosis is a rare benign neoplasm of the larynx in children; incidence is estimated about 4.3/100.000 children and extralaryngeal spread to the lower airway is relatively uncommon. Although it has a clear viral origin factors that characterize the onset and progress are still uncertain. **Materials and methods.** We report a 7 year old boy with chronic dysphonia, dyspnoea, haemoptysis and anemia who was admitted in our Clinic. The patient was submitted to left cord vocal biopsy for hoarseness. At 2 years it was diagnosed squamous papilloma and it was managed with microdebrider in another country. A laryngo-tracheo-bronchoscopy was performed with biopsies for viral identification and histology, treatment with laser CO₂, tracheotomy for diffuse papillomatosis and intralaryngeal antiviral injection. The papillomatosis was extended in glottic and subglottic. Histological report is laryngeal papillomatosis due to HPV types 11. Identification of HPV genotypes was based on PCR. **Results.** He had 3 procedures of laser CO₂ and the mean time between two consecutive surgeries was 20 days. A third laryngoscopy, after 5 week, found no lesion, no scar formation, no bleeding. The patient was discharged after 3 month. **Conclusion.** The natural history of laryngeal papillomatosis is highly variable and unpredictable. The disease may undergo spontaneous remission, persist in a stable state requiring only periodic surgical treatment, or may be aggressive, requiring surgical treatment every few days to weeks and consideration of adjuvant medical therapy. **Keywords:** laryngeal papillomatosis, laser CO₂, Cidofovir.

INTRODUCTION

Laryngeal papillomatosis is a chronic disease of viral etiology that occurs in both children and adults. The disease is caused by the human papilloma virus. The viral etiology was first suggested by Ulmann in 1923 (1) and has now been confirmed by in situ hybridization and polymerase chain reaction (PCR) for laryngeal papillomatosis (2). In most cases, HPV subtypes 6 and 11 are found. Although it has a clear viral origin, factors characterizing the onset and progress are still uncertain.

The incidence is estimated at about 4.3/100.000 among children. Approximately 75% of affected children are first-born, and these cases are usually the result of vaginal delivery; however, laryngeal papillomatosis has been reported in children born by cesarean section (3). It may occur at any site in the airway, but the glottic larynx is the most common location (4). Symptoms are hoarseness and sometimes airway obstruction. These patients are often misdiagnosed as having asthma or allergies.

Various treatment modalities have been proposed for the treatment of laryngeal papillomatosis, including surgical approaches (CO₂ laser/microdebrider) and medical treatment (cidofovir, interferon, indole-3-carbinol). However, there is general consensus that sur-

gical removal of the lesion, particularly using the CO₂ laser, is the treatment of choice (5).

Histologically, papilloma are exophytic projections of the keratinized stratified squamous epithelium overlying a fibrovascular core. Koilocytes (Fig. 1) (vacuolated cells with clear cytoplasmic inclusions) suggest the presence of a viral infection (6).

We describe a case of juvenile diffuse laryngeal papillomatosis which was spread to glottis and subglottis.

CASE REPORT

YH is a seven year old boy. He was submitted to left cord vocal biopsy for hoarseness when he was 2 years old and he received a diagnosis of squamous papilloma. When he was 6 years old he was submitted three times to surgery with microdebrider for extirpation of the papilloma in another country. On admission in our clinic the patient showed chronic dysphonia, dyspnea, emophthoe and anemia. Analysis chemistry and hemochromocitometric examination were performed, and showed elevation of PCR (1.44 mg/dls) and anemia (hemoglobin 8.3 g/dls); bone age study showed a degree of skeletal maturity corresponding at five years, less than real age 7 years; buffer pharinx, infectious markers, coproculture, urine examination and

Correspondence to:

Prof. Mario Messina, Division of Pediatric Surgery, Dept of Pediatrics, Obstetrics and Reproductive Medicine, University of Siena. Policlinico "Le Scotte" - Viale Bracci - 53100 - Siena - Italy
Telefono: +39 577 586501 - Fax: +39 577 586174
E-mail: messinam@unisi.it

urinoculture, abdomen ultrasound were negative. An esophagogastroduodenoscopy was performed to find the cause of bleeding, and it was negative. A laryngoscopy showed presence of papilloma only at left arytenoid because the patient were intubated (Fig.2). Four days after the patient was submitted to laser CO2 surgery (histology and bacteriology were performed): larynx seemed completely covered by exuberant tissue to the subglottis; considering the large extent of the papillomatosis, only the left side of the larynx was treated and the boy was submitted to tracheotomy. He also needed a blood transfusion. Six days after the patient was again submitted to laryngo-tracheoscopy that showed papillomatosis of the right side of the larynx. Fifteen days after the patient was treated with Laser CO2 surgery and topical injection of an antiviral substances (Cidofovir): papillomatous formations were removed in the left side of the larynx and in the subglottis, and the procedure was repeated after twenty days, with complete exeresis of the lesions in the right side of the larynx. The control laryngoscope after eight days showed no papilloma and intralaryngeal antiviral injection was performed (Fig.3). The patient was discharged after 3 month.

DISCUSSION

Laryngeal papillomatosis was first described in the medical literature approximately 150 years ago; since then numerous studies have investigated the epidemiology of the disease and the viral etiology, pathophysiology, clinical presentation, risk factors for aggressive disease, and staging of juvenile laryngeal papillomatosis (7). Before the advent of laryngoscopy and modern medical and surgical techniques, it is probable that many patients with laryngeal papillomatosis died for their disease without diagnosis.

Chevalier Jackson devoted a great deal of attention to the condition of papillomata of the larynx in children in his 1922 textbook, Bronchoscopy and Esophagoscopy. In addition to describing the laryngoscopic appearance, diagnostic methods, and treatment modalities for these lesions, he observed two classes of cases: non aggressive cases that tend to improve spontaneously with minimal, intermittent treatment, and aggressive cases, which were unresponsive to any form of current therapy and characterized by persistent recurrence and spread of disease. He advocated endoscopic management (8). Tissue biopsy specimens are obtained at the time of surgery. In some cases, patients present with severe, acute respiratory distress that may require tracheotomy; however, many patients undergo a tracheotomy simply to relieve obstruction from papillomas located within the larynx itself; once the larynx has been debulked and the airway restored, the tracheotomy may be removed. It has been reported that the presence of a tracheotomy increases the risk for distal tracheal spread of papillomatosis. Approximately 50% of patients with tracheotomy develop papillomas at the stomal site. Early decannulation may lead to reduced risk of tracheal stomal lesions and distal tracheal

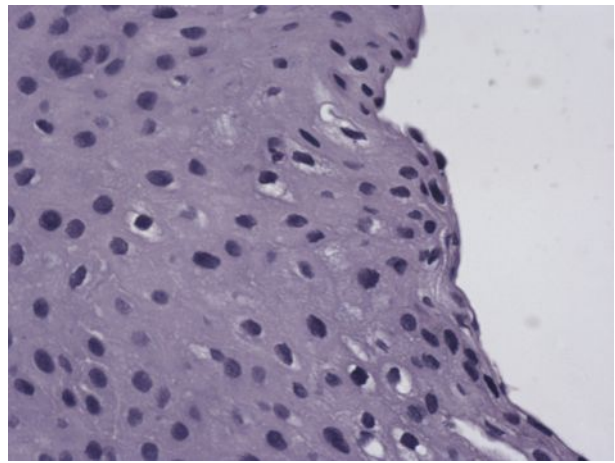


Fig.1: Histologic section of laryngeal papilloma demonstrating vacuolated koilocytes suggest the presence of a viral infection.(hematoxylin-eosin)

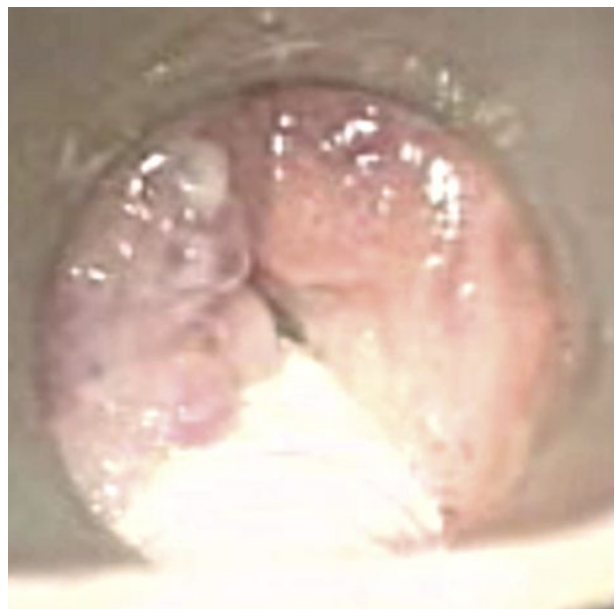
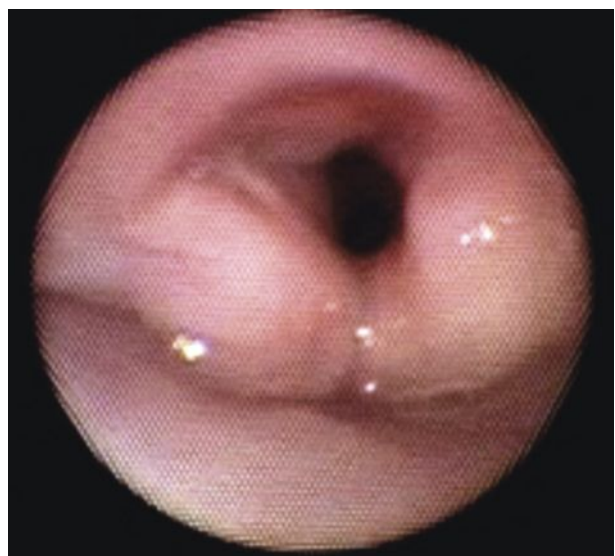


Fig.2 (above): Intraoperative image: papilloma at left arytenoid (patient intubated).

Fig.3: Postoperative laryngoscopy (2 months): absence of papillomas



spread. One study reported that patients with HPV 11 are at increased risk of requiring tracheotomy (9). Various surgical modalities have been used; however, the CO₂ laser has been used successfully for more than 30 years. The goal of surgical intervention is to provide an adequate airway, improve voice quality, and possibly facilitate remission of disease. The CO₂ allows precise removal of tissue with minimal morbidity. Thermal energy is dissipated from the surgical site to surrounding tissues, but this effect is minimal. Excessive tissue removal may result in glottis webbing or stenosis (10). Adjuvant medical therapies for laryngeal papillomatosis have been used and investigated with inconsistent results. Although some of these therapies have demonstrated efficacy in selected patients, no particular therapy is curative. Various vaccines have been suggested for the treatment of papillomatosis, including bovine wart vaccine, smallpox vaccine, and more recently, mumps vaccine. Pharmacologic approaches to the treatment of laryngeal papillomatosis have been used as an adjunct to surgical therapy: interferon α -2, but liver function abnormalities may occur with interferon therapy; topical application of estrogen has been proposed because it can thicken the mucosa, which may prevent recurrence of laryngeal papillomas. However, topical adjuvant estrogen therapy is not recommended in children, because of potential adverse endocrine sequelae.

Other adjuvant medical therapies that have shown efficacy against laryngeal papillomatosis include acyclovir, methotrexate, ribavirin, cimetidine, and more recently, cidofovir intralaryngeal injection of papillomatous lesions at the time of surgery (7).

Identification of high-risk patients could improve management of laryngeal papillomatosis by allowing earlier intervention with adjuvant medical therapies in addition to aggressive surgical therapy. Numerous clinical, viral, and molecular prognostic factors have been identified. Published data are conflicting, particularly with respect to HPV types. Rimmel et al. performed a retrospective analysis of 19 patients with laryngeal papillomatosis. Herpes papilloma virus typing was performed on paraffin-embedded biopsy specimens using PCR techniques. The authors found that patients infected with HPV 11 demonstrated a significant increase in airway obstructive disease manifesting as increases in both frequency of surgery and necessity for tracheotomy (11). Rabah et al. examine paraffin-embedded specimens from 61 adults and children, all of whom had laryngeal papillomatosis diagnosed during childhood. During follow-up periods ranging from 1 to 49 years, researchers found that disease was more aggressive in patients with HPV 11, those who underwent more frequent surgical procedures, and those with tracheobronchial disease. In some patients, malignant degeneration and death occurred (12).

CONCLUSION

The natural history of laryngeal papillomatosis is highly variable and unpredictable. The disease may

undergo spontaneous remission, persist in a stable state requiring only periodic surgical treatment, or may be aggressive, requiring surgical treatment every few days to weeks and consideration of adjuvant medical therapy. A meticulous follow-up for early recognition of local recurrence and malignant transformation and secondary carcinoma is recommended.

REFERENCES

1. Ullmann Ms. *On etiology of the laryngeal papilloma. Acta Otolaryngol (Stockh) 1923; 5:315-25.*
2. Abramson Al, Steinberg BM, Wingler B. *Laryngeal papillomatosis: clinical, histopathologic and molecular studies. Laryngoscope 1987; 97:678-85.*
3. Simon Florian Preuss, Jens Peter Klussmann, Markus Jungehulsing, Hans Edmund Eckel, Orlando Guntinas-Lichius & Michael Damm. *Long-term results of surgical treatment for recurrent respiratory papillomatosis. Acta Oto-laryngologica, 2007; 127:1196-1201*
4. Derkay CS, Wiatrak B. *Recurrent respiratory papillomatosis: a review. Laryngoscope 2008; 118:1236-1247.*
5. Annette J. Van Nieuwenhuizen; Rico N. P. M. Rinkel, MD; Remco de Bree, MD; C. Renè Leemans, MD, PhD; Irma M. Verdonck-de Leeuw, PhD. *Patient reported voice outcome in recurrent respiratory papillomatosis. The laryngoscope 000:000-000, 2009.*
6. Green GE. *Juvenile-onset recurrent respiratory papillomatosis. In: Ossof RH, ed The Larynx. Philadelphia: Lippincott Williams and Wilkins; 2003:479-496.*
7. Brian J. Wiatrak, MD; Deborah W. Wiatrak, MD; Thomas R. Broker, PhD; Linda Lewis, MSN, RN, CNS. *Recurrent respiratory papillomatosis: a longitudinal study comparing severity associated with human papilloma viral types 6 and 11 and other risk factors in a large pediatric population. The Laryngoscope 114: November 2004.*
8. Jackson C. *Benign growths in the larynx: bronchoscopy and esophagoscopy. In: A Manual of Peroral Endoscopy and Laryngeal Surgery. Philadelphia: WB Saunders, 1992:203-208.*
9. Shapiro AM, Rimmel FL; Shoemaker D, Pou A, Stool SE. *Tracheotomy in children with juvenile-onset recurrent respiratory papillomatosis: the Children's Hospital of Pittsburgh experience. Ann Otol Rhinol Laryngol 1996;105:1-5.*
10. Deskin RW. *Laser laryngoscopy for papilloma removal. In: Bailey BJ, ed. Atlas of head neck surgery-otoryngology. Philadelphia: Lippincott-Raven; 1998:237-245.*
11. Rimmel Fl, Shoemaker DL, Pou AM, Jordan JA, Post JC, Erlich GD. *Pediatric respiratory papillomatosis: prognostic role of viral typing and cofactors. Laryngoscope 1997;107:915-918.*
12. Rabah R, Lancaster WD, Thomas R, Gregoire L. *Human papillomavirus-11-associated recurrent respiratory papillomatosis is more aggressive than human papillomavirus-6-associated disease. Pediatr Dev Pathol 2001;4:68-72.*