

**SURGERY AND TRANSLATIONAL LYMPHOLOGY:  
MODELS FOR EDUCATIONAL PROGRAMS, RESEARCH AND CLINICAL APPLICATIONS**

Campisi C.<sup>1</sup>, Boccardo F.<sup>1</sup>, Campisi C.S.<sup>1</sup>, Campisi C.C.<sup>2</sup>

<sup>1</sup>Dpt.of Surgical Sciences and Integrated Diagnostics (DISC), IRCCS (Institute of Research and Care at Scientific Character), University Hospital San Martino –IST, Genoa, Italy

<sup>2</sup>Dpt.of Health Sciences (DISSAL), IRCCS (Institute of Research and Care at Scientific Character), University Hospital San Martino –IST, Genoa, Italy

**Abstract.** A wide clinical experience in General Surgery has brought about a remarkable knowledge about lymphatic disorders both primary and secondary ones. Diagnostic and histopathological studies of lymphatic diseases allowed to better understand etiological aspects and pathophysiological mechanisms responsible of complex clinical features correlated to lymphatic dysfunctions. Translational lymphologic basic and clinical researches permitted to improve therapeutical approaches both from the medical and surgical point of view. Thus, strategies of treatment were proposed to prevent lymphatic injuries, to avoid lymphatic complications and to treat lymphatic diseases early in order to be able even to cure these pathologies.

**Keywords:** Lymphatic diseases, pathophysiology-Therapeutics- Microsurgery

Recent advances in microsurgery, refinements in non-invasive dynamic lymphatic system imaging, and improved approaches to resection involved the contributions of pioneering surgical lymphologists to make lymphatic microsurgery and surgery of lymphatic disorders an increasingly important, safe and practical option in these chronic vexing disfiguring, disabling, and at times, life-threatening congenital and acquired conditions. Moreover, future improvements in the scope and outcome of these procedures include minimally invasive and robotic approaches possibly coupled along with tissue engineering, stem cell and tissue transplantation. These improvements, and ultimately fetal restitution/reconstruction, to prevent or treat these lymphatic disorders will require both the intellect and skill of the surgeon on the research teams and in clinical multimodal management (4) (Figg.1-2, side)

**EVOLUTION OF LYMPHATIC MICROSURGERY**

The first use of microsurgery was described in 1962 when Cockett (5) and Goodwin performed an anastomosis of a dilated lumbar lymphatic to the spermatic vein to treat a patient with chyluria. From this first procedure, subsequent developments in microsurgical techniques (as described below) have enabled lymphatic-venous anastomosis to emerge as a feasible treatment option for lymphedema.

O'Brien and co-workers (6,7) in 1977 described their use of microlymphatic surgery for treatment

*Landmarks in Lymphology*

1. Discovery of the chyloferous vessels and first lymphatic imaging – Aselli, 1627 – Pecquet, 1651
2. Vasorum lymphaticorum corporis humani historia et ichonographia – Mascagni, 1787
3. Transcapillary exchange of liquid, lymph formation and edema - Starling, 1895
4. Embryology and phylogeny of lymphatic system - Sabin, Kampmeier, 1903
5. Structure of lymphatic capillaries, lymph vessels and nodes Comparini, Ottaviani, 1930 - 1958
6. Lymphangiogenesis *in vivo*, 1932, and *in vitro*, 1984
7. Lymphocyte migrant streams - Yoffey, Morris, Gowans, 1939
8. Lymphatic imaging / classification Kinmonth, Servelle, Kaindle, 1950 – Tosatti, Acconcia, Armenio, 1956
9. Intrinsic contractility and distinctive ultrastructure of lymphatics – Hall, Roddie, Casley-Smith, Leak, 1962
10. Lymphostatic disorders /edematous syndromes – Rusznayak, Szabo, M & E Foldi, Olszewski, Dumont, M & C Witte, 1960
11. Lymphatic Microsurgery – Olszewski, Degni, Campisi, 1966 - 1973 - 1981
12. Lymphoscintigraphy including sentinel node mapping, 1970
13. Highly specific molecular/histochemical markers - Lyve-1, Prox-1, Podoplanin, 5' nucleotidase, VEGFR-3, 1990
14. Lymphatic growth factors/genetics – Alitalo, 1996 / Teams U Pittsburgh, U Conn - St George, U Az - U Mich, 1998, U Leuven, 2003

*Translational Lymphology*

- ✓ Recent discoveries of lympho-vascular genes and proteins in the field of Molecular Lymphology built a bridge between Basic Lymphology and Clinical Lymphology.
- ✓ Today is possible to rapidly obtain the genotype of families affected by lymphatic dysplasias and therefore correlate it with the peculiar clinical and lymphatic phenotype.
- ✓ The challenge consists of integrating the distinctive molecular intuitions that permeate Clinical Lymphology, leading to potential achievements, from research to clinical practice, favouring the community, in order to improve the life of the patients.
- ✓ Vice versa, unsolved clinical demands can be returned to further laboratory studies.

Correspondence to:

Prof. Corradino Campisi

Operative Unit of General Surgery and Lymphatic Surgery, Dpt. of Surgery, IRCCS (Institute of Research and Care at Scientific Character), University Hospital San Martino –IST, National Institute for Cancer Research, Genoa, Italy

Telefono: (+39) 0105600-125/-861

E-mail: campisi@unige.it

of secondary obstructive lymphedema. They utilized three or more lymphaticovenous anastomoses at or above the elbow (or knee) and observed a reduced incidence of cellulitis post-operatively. The microlymphatic techniques were applicable to both upper and lower limbs, and they also applied them to localized cases of obstructive lymphedema following trauma and congenital constriction bands. They emphasized that considerable experience in microvascular surgery was required for performing the procedure. Their results in obstructive secondary lymphedema were encouraging, even though the authors remarked that a long-term evaluation of the clinical outcome was required before judging the potential of these techniques.

The field was advanced in 1981 when Degni (8,9) introduced an original technique of lymphatic-venous anastomosis for use in lymphedema of the limbs. The procedure was easily performed and was applicable to both the upper and lower limbs, and also for the thoracic duct or any blocked lymphatic vessels of the abdomen. He used this technique to treat lymphedema due to surgical resection of benign tumors (lipomas of the thigh), reconstructive procedures (pendulous abdomen, plastic surgery of the thigh), orthopedic operations on the knee, and after varicose vein stripping. The purpose was to divert the lymph into a vein in cases of blocked lymphatic vessels, particularly when lymphographic findings demonstrated good function and intact permeability of lymphatic vessels. A longitudinally divided needle was used to introduce the lymphatic trunk into the vein, pulling the lymphatic into the venous lumen and fixing the lymphatic to the upper venous wall with one suture.

At almost the same time (1982), Clodius (10,11) reported that microsurgery for primary and secondary lymphedema, consisting of shunts between lymphatic vessels and veins, was a well-established surgical technique. Problems arose from irreversible changes in the peripheral lymphatic system and in the connective tissues as well as the obliteration of the deep lymphatics best suited for lymphaticovenous anastomoses in more chronic lymphedema. He therefore cautioned that lymphaticovenous shunts should be performed early before fibrotic tissue changes appear.

As the techniques were becoming more widespread, two groups reported larger data sets. In 1985, Huang and co-workers (12) described their experience of 110 cases of lymphedema treated by microlymphaticovenous anastomosis with very satisfactory immediate and long-term results in 79.1%. Their data suggested that the quality of results was proportional to the number of anastomoses. Krylov and co-workers (13) reported an experience of 510 patients with primary (~2/3 of cases) or secondary lymphedema in upper and lower extremities. Notably, the most favorable results were obtained in secondary obstructive lymphedema cases associated with lymphatic hypertension, which contributed to better functioning of the lymphaticovenous anastomoses. In 1987, Zhu and co-workers (14) reported a clinical experience of 185 limbs with lymphedema treated by lymphaticovenous

anastomosis with excellent results achieved in 73% of the cases.

Al Assal, Cordeiro and co-workers (15), in 1988, reported experimental studies in dogs using a new technique of microlympho-venous anastomosis to improve long-term patency rates and clinical results in lymphedema therapy. Technical points, such as an oval window on the wall of the vein and a few sutures piercing only two lymphatic layers, adventitia and media, outside the lumen were emphasized for successful results. Three methods for assessment of patency of anastomoses were used: (1) observation with the operating microscope of dye transit across the anastomotic site; (2) lymphography, and (3) histopathologic examination. Based on encouraging results, the authors suggested that end-to-side anastomosis might be the technique of choice.

Olszewski (16-19) published in 1988 his personal 20-year clinical experience in diagnosis and treatment of various types of lymphedema of the lower limbs with microsurgical lymph node-vein and lymph vessel-vein anastomoses. He limited indications for surgical therapy of lymphedema to a carefully selected group of patients with local, segmental obstruction of proximal lymphatics with demonstrably patent peripheral lymphatics and at least partial preservation of contractility. He reported that in his practice long-term penicillin therapy was indispensable prior to surgery in cases with a history of lymphangitis.

A critical review of microsurgical lymphovenous anastomosis for the treatment of lymphedema was published by Glociczki and co-workers (20) in 1988. Their group performed lymphovenous anastomoses (LVA) to treat chronic lymphedema and reported a mean follow-up at 36.6 months. They concluded that LVA offered a promising physiologic treatment particularly in the secondary lymphedemas and that lymphoscintigraphy was found to be a suitable method for both identifying patent lymphatic channels before surgery and determining function of LVA after operation.

Ho and co-workers (21), also in 1988, reported their results in a series of patients with secondary obstructive lymphedema treated by microlymphatic bypass. The procedures in the lower and upper limbs were described. Preoperative assessment by lymphangiography and lymphoscintigraphy was used to assess suitability for the procedure. Postoperatively, patent lymph collectors were demonstrated by lymphoscintigraphy. The authors also emphasized that microlymphatic bypass should be carried out before the peripheral lymph collectors were destroyed or permanently damaged by increasing back pressure and recurrent infection.

In a different approach, Baumeister and Siuda (22) in 1990 described their initial experience with microsurgical lymphatic grafting in the treatment of lymphedemas. Lymphatic grafts were anastomosed to peripheral lymphatics distal to and central lymphatics proximal to the regional blockade. In the case of unilateral blockade at the groin or pelvis, the grafts connected the lymphatics of the thigh of the affected leg with lymph-

phatics in the contralateral healthy groin. They have continued to perform this procedure albeit in a relatively small number of selected cases, using lymphoscintigraphy to document graft patency.

In 1990, O'Brien and co-workers (23,24) reported on their cumulative clinical experience in the treatment of obstructive lymphedema by microlymphaticovenous anastomoses. They described subjective improvement in 73% of patients and, objectively, volume changes showed a significant improvement in 42% of cases, with an average reduction of 44% of the excess volume. The authors also emphasized the significant reduction in the incidence of cellulitis episodes following surgery. Their long-term results (average follow-up of 4 years) indicated that microlymphaticovenous anastomoses had a valuable place in the treatment of obstructive lymphedema and perhaps should be the treatment of choice in select patients. They also pointed out (as Clodius and Ho above) that improved results could be expected with earlier operations because patients referred earlier usually have less lymphatic disruption. Despite advances in microsurgery, the most suitable operation for primary lymphedema remained unclear. (24b) A variety of tissue transplants and artificial substances had been used to facilitate drainage of peripheral lymph (25,26). The greater omentum was used experimentally in the treatment of canine obstructive lymphedema by O'Brien and co-workers in 1990 (27) and Abalmasov and co-workers in 1994 (28). The findings indicated that experimental obstructive lymphedema in the dog could be reduced significantly by insertion of a vascularized omental graft. However, because there is no natural lymph nodal-venous (L-V) shunt within the greater omentum, the addition of an L-V shunt to omental transplantation in dogs seemed to increase effectiveness of the autotransplanted omentum for draining hindlimb lymph. Continued use of omental transplants has continued in select situations.

#### LYMPHATIC MICROSURGERY AND SURGICAL APPROACHES TO LYMPHEDEMA: CLINICAL AND TECHNICAL ASPECTS

##### *Derivative Approaches*

The first microsurgical derivative operations were those using lymph nodal-venous shunts. These have been largely abandoned (except in endemic areas of lymphatic filariasis such as India where thousands of these procedures have been performed and lymphatic channels even in lymph nodes are often widely dilated) due to the high rate of anastomotic closures caused by the thrombogenic effect of lymph nodal pulp on the venous blood and the frequent re-endothelialization of the lymph nodal surface. One of the possible modifications of this technique is the use of lymph nodal capsular patch with its afferent lymphatics (lymph nodal capsular-venous anastomosis). This method has been carried out predominantly in children since it is technically feasible even in cases of very small lymphatic and venous structures.

Because of the difficulties encountered with lymph

nodal-venous shunts by surgeons worldwide, the next approach was to use lymphatic vessels and directly anastomose them to veins. The first of these operations at the University of Genoa were performed using an end-to-side (lymph to blood) technique (29). Lymphatic collectors were introduced inside the vein, and the inferior edge of the lymphatics introduced into the vein lumen acted as valves to avoid backflow of blood into the lymphatics and there by preventing occurrence of thrombosis. More recently, the preferred techniques has been telescopic multiple lymphatic-venous anastomoses. Healthy appearing lymphatics found at the site of surgical operation are directly introduced together into the vein by a U-shaped stitch and then fixed to the vein cut-end by means of additional stitches between the vein border and the perilymphatic adipose tissue. At the end, the first U-shaped stitch is removed to avoid the risk of closure of lymphatic collectors. With the use of Patent Blue dye (a sodium or calcium salt of diethylammonium hydroxide), properly functioning lymphatics appear blue, and the passage of blue lymph into the vein branch verifies the patency of the lymphatic-venous anastomosis under the operating microscope when the anastomosis is completed.

For patients with lower limb lymphedema, anastomoses are performed at the sub-inguinal region. Lymphatic-lymph nodal superficial structures are isolated, and all afferent lymphatics are used for the operation. Lymph nodes are subjected to histopathologic examination. The usual finding in primary lower limb lymphedemas is a varying grade of nodal fibrosclerosis and thickening of the nodal capsule but with normal afferent lymphatic vessels.

There are alternative technical microsurgical solutions depending on the anatomical conditions at the site of operation. It is possible to perform multiple lymphatic-venous anastomoses at the same time, and the important feature is that the vein branch is patent. It is necessary to test the patency of venous valves since it is mandatory to carry out an external valvuloplasty to correct the valvular insufficiency before performing anastomoses in cases of incompetent venous valves (30,31).

For upper limb lymphedema, lymphatic-venous anastomoses are performed at the medium third of the volar surface of the arm, using both superficial and deep lymphatic collectors, evidenced by the blue dye. Deep lymphatics are found in between humeral artery, vein and the median nerve. The vein used for anastomoses is a patent branch of one of the humeral veins, and the technique most performed is the telescopic one.

More than 2500 patients affected by peripheral primary and secondary lymphedema have been treated over the past 40 years at the University of Genoa mostly using lymphatic-venous derivative techniques. Primary lymphedemas largely included lymph nodal dysplasias (LAD II, according to Papedieck's classification (32,33) consisting of hyperplastic lymph nodes with sinus histiocytosis and a thick and fibrous capsule with microlymphangiadenomyomatosis. In these cases, lymph flow obstruction was apparent as seen by alter-

ations of the afferent lymphatics which appeared dilated and swollen with thickened walls and where smooth muscle cells are reduced in number and appear fragmented by associated fibrous elements (34). In our experience, secondary lymphedemas (35-37) were largely due to lymphadenectomy and radiotherapy performed for oncological reasons (carcinoma of the breast, uterus, penis, bladder, prostatic gland, rectum, and seminoma of epididymis), as well as for complications of minor operations for varicose veins, crural and inguinal hernias, lipomas, tendinous cysts, or axillary and inguinal lymph node biopsies. Most of the lymphedemas treated by microsurgery were at stages II (39%) and III (52%), while 3% of the patients were stage Ib and 6% were stages IV and V.

Lymphoscintigraphy, performed with either  $^{99m}\text{Tc}$ -labeled antimony sulfur colloid or  $^{99m}\text{Tc}$ -nanocolloid Human Serum Albumin (90% of the particles  $>80$  nm in size), was employed in the diagnostic work-up of patients with lymphedema and as a test for selecting patients for derivative microsurgical operations. Lymphoscintigraphy clearly discriminated whether or not edema was of lymphatic origin and also provided important data about the etiologic and pathophysiologic aspects of the Lymphedema (38-47).

Echo Doppler was performed in all patients to identify any venous disorders possibly associated with lymphedema. In most patients, venous dysfunctions were corrected at the same time of microlymphatico-venous anastomoses (i.e., valvular plasty in case of venous insufficiency). In other cases, finding venous dysfunction contraindicated derivative lympho-venous shunts but at the same time facilitated referral of the patient for reconstructive microsurgical operations.

Conventional oil contrast lymphangiography was employed only in selected patients with lymphedema due to gravitational reflux in order to define more clearly the extension of the pathologic alterations and sites of lymphatic and chylous leakage (48-50).

#### *Reconstructive Techniques*

In those cases involving the lower limbs, where surgically uncorrectable venous disease exists, it is not advisable to use derivative lymphatic-venous techniques, and accordingly, reconstructive methods are used (51-53). The most commonly used technique is the interposition of an autologous vein graft between lymphatics above and below the obstacle to lymph flow. The venous segment can be obtained from the same operative site or from the forearm (mostly the cephalic vein). The length of the graft is variable from 7 to 15 cm, and it is important to collect several lymphatics at the distal cut end of the vein so as to maintain the segment filled with lymph and avoid closure due to fibrosis. The valves of the veins are useful for the correct direction of the lymphatic flow and to avoid gravitational backflow. The technique of anastomosis is the telescopic one with introduction of lymphatics inside the vein cut ends by a U-shaped stitch, which is then fixed by some peripheral stitches (54-56).

#### *Patients, Timing, and Results*

Clinical outcome improves the earlier microsurgery is performed owing to absent or minimal fibrosclerotic alterations of the lymphatic walls and surrounding tissues. Long term results after more than 10 years have been excellent (over 75% excess limb volume reduction, compared with pre-operative conditions) in 83% of patients, good (25-50% decrease) in 14%, and poor (less than 25% edema reduction) in 3%.

Lymphoscintigraphy helps in verifying the patency of microanastomoses long term after operation by direct and indirect findings: reduction of dermal backflow together with the appearance of preferential lymphatic pathways not visible before microsurgery; disappearance of the tracer at the site of lymphatic-venous anastomoses due to direct tracer passage into the blood stream; and earlier liver uptake compared to pre-operative parameters (indirect patency test).

The optimal indications for lymphatic microsurgery are represented by: early stages (1b, 2a,, early 2b); lymphoscintigraphy showing a low inguinal or axillary lymph nodal uptake and minimal or absent passage of the tracer beyond this proximal nodal area; excellent patient compliance; and a lymphological center where the patient can easily refer for any needs in addition to a Center of Lymphatic Surgery where the patient undergoes this specialized surgery.

At later stages (advanced 2b,3a, and 3b), with absent visualization of lymphatic channels and regional lymph nodes, it is necessary to reduce the stage of the lymphedema by non-operative methods before microsurgery. After operation, it is particularly important for these patients to be followed closely to improve the clinical outcome and maintain the short-term operative results for the long term (so called CLyFT therapy). In case of poor patient compliance, the results may be unsatisfactory. Relative contraindications to lymphatic microsurgery are represented by cases of lymphatic-lymph nodal aplasia (extremely rare), diffuse metastatic disease, and advanced stage (V) not responsive to conservative therapy.

Lymphatic microsurgery represents a means to bypass the obstacle to lymph flow through lymphatic-venous drainage (lymphatic-venous anastomoses) or by using venous grafts between lymphatic collectors below and above the obstruction (lymphatic-venous-lymphatic plasty) (57-62). Combined physical therapy (63-75) nonetheless represents the initial treatment of patients affected by peripheral lymphedema and it is best performed in specialized centers. The surgical timing follows completion of conservative treatment when further clinical improvement can no longer be achieved and/or recurrent lymphangitic attacks are not further reduced. Microsurgical operations can then be performed and provide further improvement in the condition.

Traditional debulking operations are presently less utilized to treat lymphedema except in cases of late stage lymphedema to reduce skin folds after marked edema reduction obtained by conservative physical and microsurgical methods; in body regions relatively inac-

cessible to effective compression such as the genitalia; in advanced lymphatic filariasis at times combined with lymphatic-venous or nodal-venous anastomosis in the setting of widely dilated lymphatic channels (76); and in localized lipolymphedema associated with massive obesity and forced immobility.

In recent years, liposuction techniques have been refined by Brorson and colleagues in their specialized center at the University of Malmö, Sweden and replicated in a few other locations worldwide. This technique can be very effective in reducing the volume of bulky lymphedematous arms even in late stages. A much smaller experience with lower limbs has also been reported by the Swedish group. The patients must use life-long round-the clock compression garments thereafter and maintain full compliance to sustain the cosmetic and volume reduction results long-term.

**MANAGEMENT OF LYMPHATIC TRAUMA**

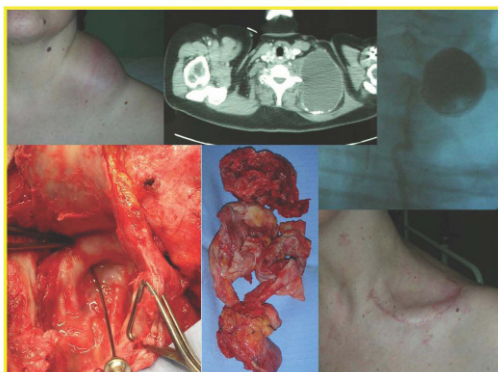
Traumatic chylothorax and chylous ascites can follow blunt or penetrating trauma. While initially managed non-operatively, operation may become necessary if the chylous leakage persists and becomes life-threatening. Surgical options (Figg.3-4-5) range from direct surgical repair of the thoracic duct or lymphatic ligation to thoracic duct or mesenteric lymphatic-venous shunts (77). Rarely, Denver-LeVeen or other types of peritoneo-venous shunt devices have been used successfully.

*Surgery and Translational Lymphology*

- ✓ Traumas
- ✓ Infections
- ✓ Lymphedemas
- ✓ Pathology of the Chyliferous Vessels, of the Cisterna Chyli and of the Thoracic Duct
- ✓ Tumors
- ✓ Surgery and Prevention of Lymphatic Lesions

3

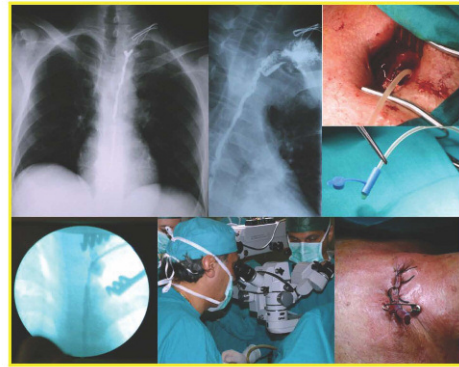
*Traumas*



*Post-traumatic Left Supraclavicular Lympho-Chylocele*

4

*Traumas*



*Thoracic Duct Iatrogenic Lympho-Chyloous Leak*

5

**LYMPHANGIODYSPLASTIC AND CHYLOUS AND NON-CHYLOUS REFLUX SYNDROMES**

Abnormal retrograde transport of lymph or reflux can derive from outside the intestine (non-chylous) or arise in the intestine (chylous or milky in appearance). The phenomenon was recorded as far back as Cruikshank (78), who considered it a post-mortem phenomenon in cadavers. Busey in 1878 (79) described patients with chylous and non-chylous reflux syndrome with accompanying lymphedema and expressed his frustration with inability to improve their condition. Because cholesterol and long-chain triglycerides as chylomicra are absorbed exclusively by the lymphatic system, disruption, compression, obstruction or fistulization of mesenteric lacteals, the cisterna chyli, and the thoracic duct directly relates to chylothorax, chylous ascites, chyluria, and chylous reflux in other sites. In some patients with severe obstruction to intestinal lymph flow, the peripheral lymphatics gradually dilate, valves become progressively more incompetent, and lactescent lymph refluxes into the soft tissues of the pelvis, scrotum, and lower extremities (chylous vesicles), and even manifests as generalized subcutaneous chyledema in newborns. A variety of genetic mouse models mimic this condition with diverse developmental defects of the intestinal-thoracic duct lymph system.

Dynamic imaging of both chylous and non-chylous lymph reflux can usually be obtained by adjusting the whole body protocol for lower and also rarely upper limb lymphangioscintigraphy and can be applied to newborn infants as well as adults to identify the source, timing and location of the lymph reflux and tailor further evaluation and management accordingly (77-83).

*Pathophysiology*

From the etiopathological point of view, primary forms of chyloperitoneum are basically correlated with congenital dysplastic alterations (87-92) and more or less extended malformations of chyliferous vessels, cisterna chyli, and/or of the thoracic duct, as well as of regional lymph nodes in this region or in affected regions. These conditions account for approximately 70% of all cases.

Conversely, "secondary" forms due to mechanical causes or obstructions of various types or disruptions, including trauma, are less common.

It should be pointed out that from a pathophysiologic point of view, malformation-related dysplastic alterations act as actual obstacles to antigravity lymph drainage, just like mechanical obstruction. A malformation affecting the thoracic duct, Pecquet cyst, and/or chyliferous vessels illustrates this concept and represents a significant obstacle to lymph drainage and, in particular, to intestinal drainage. Accordingly, chyliferous vessels along the walls of the small intestine and of the mesentery become significantly dilated and abnormally stretched due to chylous stasis. The disease also features lymphatic megacollectors with more or less extensive chylous lymphangiectasia, often associated with lymphangiomyomatosis. These are not only located right below the visceral peritoneal layer with a mesh-like arrangement, but also throughout the small intestine and more specifically at the level of intestinal villi. Hence, dysplastic chyliferous megalymphatics may rupture due to a localized swelling (the so called "mesentery chylous cyst") or anywhere along the wall of an extremely ectatic collector, sometimes through a two-step process, that is, once the peritoneum is opened up by chyle with subsequent development of a "chyloma," chyle begins to flow into the abdominal cavity. Also, in other cases, the chyliferous vessel at the center of the villus breaks into the intestinal lumen, thereby causing the loss of proteins, lipids, lipoproteins, and even calcium and glucose, which leads to metabolic disorders that are typical of so called "Protein Losing Enteropathy" (PLE).

Owing to the direct link between the septic intestinal environment and the inner lining of chyliferous vessels, there may be recurrent attacks of acute lymphangitis and acute mesenteric lympho-angioadenitis which, in some cases, may even lead to septic shock or, at best, to a chronic process, while triggering a vicious circle with further worsening of the intestinal lymphatic drainage.

Chyloperitoneum and PLE may often be combined. Also, it should not be forgotten that, apart from intestinal lymphatics, also lumbar lymphatics – collecting the lymph from the lower limbs, external genitalia, intra-abdominal organs, kidneys, adrenal gland, and the abdominal wall – flow into the cisterna chyli. Further, considering the thoracic-mediastinal catchment basin of the thoracic duct and that lymphatic dysplasias can affect even one or more extra-abdominal sites, due to bizarre malformation combinations, chyloperitoneum can also be associated with a whole range of different pathologic pictures: mono or bilateral chylothorax; chylous cyst, mediastinal chyloma or chylo-mediastinum; chylopericardium; chyluria; chylo-colpometorrhoea; chyloedema of external genitalia and/or of one or both lower limbs, with chylo-lymphostatic verrucosis and subsequent chylo-lymphorrhoea; and chylous joint effusion.

The wide ranging extension of the foregoing malformations and the complexity of their association with

dysplasia of chylo-lymphatic vessels, thoracic duct, and chylous cyst explain why, in the newborn, sometimes these conditions affecting multiple sites are incompatible with life (93). Further, upon clinical onset of the most severe cases, effective treatment may be difficult to achieve later in life, thereby leading to more or less complex prognostic implications involving "quoad valetudinem" as well as "quoad vitam" issues.

#### *Treatment Approaches*

For a rapid restoration of proper metabolic balance, total parenteral nutrition (TPN) is recommended early on in order to significantly limit the chylous leak volume.

In the initial approach to this complex problem, especially in acute and sub-acute onset cases, a videolaparoscopy can be useful and also indicated to help in the proper positioning of one or more peritoneal drains of correct size. These will be used to drain the effusion in one or more steps, depending on its volume, while taking care not to cause "ex vacuo" hemorrhages and keeping in mind that chyle is a dense fluid. This procedure is preferred over the ultrasound or CT guided positioning of smaller drains, which are more likely to become closed over time.

Once in place, these drains can be used "on demand," also for washings with a Trémollières sterile solution (concentrated lactic acid) combined with an antibiotic (250-500 mg of sodium rifampicine). The sclerosing effect of this drug has proven beneficial, especially in the treatment of post-surgical chyloperitoneum (mostly occurring after lymph node resections performed close to the mesenteric root). Also, in these cases of surgical origin where the onset of chyloorrhagia occurs in the early days after surgery and can be observed through the same drains placed upon surgery completion, in the great majority of cases, washing with Trémollières associated with a rigorous total parenteral feeding has proved to be successful in resolving this condition in two or maximum three weeks. Actually, the great majority of chyloorrhagia cases have been due to extended lymphadenectomy in kidney cancer surgery. In this way, timely treatment of chyloorrhagia as a post-operative complication can help prevent the onset of secondary chyloperitoneum. This complication is common in oncological surgery particularly when abdominal drains are removed too early.

On the other hand, primary chyloperitoneum caused by dysplasia or malformations is a much more complex condition. An accurate diagnostic assessment is required for proper treatment, depending on associated clinical features, namely:

- $^{51}\text{CrCl}_3$  test, to gain evidence of any major abdominal protein leak (>2% of fecal radioisotope disposal within 5 days following intravenous –  $^{51}\text{Cr}$  – administration of this substance. Especially in children, care must be taken not to mix feces with urine since ~ 30% of this isotope is excreted in the urine.
- Small intestine barium enema, to demonstrate any notable thickening due to lymphedema, which is generally greater in the submucosa of the intestinal wall, and

subsequent protrusion of intestinal folds and villi;

- Small intestine endoscopy, in particular with biopsy of the duodenum-jejunum segment, which shows significantly stretched chyliferous vessels at the centre of villi;

- Lymphoscintigraphy, with evidence not only of tracer leak into the peritoneal cavity, but also of a more or less severe dysplasia involving also other compartments, like external genitalia and the lower limbs. This method is an excellent tool to assess microsurgery outcome (as we illustrate below);

- Standard lymphangiography with liposoluble ultrafluid contrast medium injected with microsurgical technique after isolation and cannulation of the lymphatics of the extensor digitorum muscle. If coupled with a CT scan, LAG allows a more accurate assessment of disease extension, as well as the site of the obstacle and source of chylous leak;

- Magnetic resonance which, by digital subtraction method of the fatty tissue, offers a more in depth demonstration of dysplasia-related impairment of the lymph vessels (lymphangiogram) (94).

In order to demonstrate a concurrent Protein Losing Enteropathy (PLE), albumin labeled (99m Tc) scintigraphy may be quite useful for a more complete diagnosis. PLE can be observed inside the intestinal lumen in scans taken 1-24 hours after intravenous administration of 740 mBq.

Finally, in case of even more complex pictures associated with more or less widespread hemangiodysplasias, selective digital angiography of the compartments affected by vascular visceral and/or peripheral malformations, and angio-CT are helpful complements to the aforementioned instrumental diagnostic process. At this point, surgical intervention depends on the outcome of the various conservative treatments already implemented, namely, hyperprotein and hypolipidic diet (e.g., exclusively based on medium-chain fats and triglycerides) and total parenteral nutrition (TPN); proper antibiotic protection, which is necessary to prevent and treat the not uncommon septic complications; and even serial paracentesis, which mainly aims at gradual chylous effusion drainage and subsequent reduction in intra-abdominal pressure. In this as well as in subsequent treatment phases, the intravenous, intramuscular, and/or subcutaneous administration of somatostatin or octreotide (the synthetic form) can be useful in reducing chylous effusion – in some cases remarkably successful – likely related to their pitressin-like effect and even as anti-proliferation agents in vascular and, more specifically, lymphatic cells and endothelium (95).

#### *Surgical Treatment*

Therefore, surgery should be designed on a case by case basis, depending on the primary or secondary nature of chylous effusion, clinical severity, and the number of chylous leaks. The following types of surgical approaches can be performed to treat this disease depending on the specific clinical condition and prior response (96-98):

- *Chyloperitoneal drainage;*
- *Identification of the site or sites of chylous leakage;*
- *Removal of chylous cysts and/or chylomas;*
- *Resection of lymphangiectatic -lymphangiodysplastic tissue, which can also be combined with other ad hoc solutions;*
- *"Spaced-out" antigravity ligatures of incompetent and ectatic chyliferous lymphatic vessels, in order to treat gravitational chylous reflux – following the techniques of Servelle and Tosatti – and if necessary, also*
- *CO<sub>2</sub>-Laser: When applied at low power, this technique has a welding effect on lymphatics and many other tissues and blood vessels up to one mm diameter;*
- *Derivative (lymphatic-venous anastomosis) or reconstructive (lymphatic-venous-lymphatic plasty) microsurgery: When applicable, efficacy has been extensively documented. With well demonstrated techniques, functional solutions can be fashioned allowing for anti-gravitational discharge into lumbar, iliac-pelvic, and inguinal lymph nodes – depending on each case – and, when suitable, ectatic collectors can be harvested.*
- *In the most difficult cases and those affected by repeated recurrences, a peritoneo-jugular shunt (Denver, Le Veen type), which, however, has major limitations in children and is susceptible to thrombosis from the viscous chylous lymph.*
- *In extreme cases, entero-mesentery lymphangiectasia may be so severe that a full resection of the intestinal segment prominently affected by dysplasia may be required and, in the extreme, intestinal transplantation performed.*
- *Videolaparoscopy as a support to laparotomy: When the former cannot be performed as an exclusive procedure – and often associated with CO<sub>2</sub> Laser assisted microsurgery – this approach has been particularly helpful. For better recognition of chyliferous vessels, the administration of a fatty meal (60 g of butter in a cup of milk) is useful 4-5 hours before surgery.*

#### **RESULTS**

Sixteen patients (14 males, 2 females) at the University of Genoa have been treated surgically for primary chylous ascites. The group consisted of 6 children between 9 months and 12 years old (median, 8 years) and 10 adults from 23 to 56 years old years (median, 35 years). All patients were initially treated by a medical approach alone. They were fed by TPN for a mean of 2 weeks and depending on the presence of the chylous ascites, one or two peritoneal drainages were placed into position by laparoscopy. After draining all chylous ascites, the open surgical procedure began by removing all dysplastic tissues at the site of the chylous leakage by multiple lymphatic and chylous ligatures using nonabsorbable suture material and CO<sub>2</sub> laser welding effect. Afterwards, suitable lymphatic or chylous vessels were used to perform lympho-venous shunts on mesenteric or iliac veins. Three drainage tubes were left inside the abdomen, two in the parietocolic area and one in the pouch of Douglas. TPN was extended for 10 days and afterwards, appropriate oral feeding was progressively introduced. Drainage tubes were re-

moved 10 to 15 days after surgery.

Early relapse of chylous ascites was observed in only one case, which required a peritoneo-jugular shunt, which produced a good outcome. All patients must follow an appropriate diet. Bowel resection was not required in any of the patients. One patient with chyluria was treated by resection of the perirenal lymphatic vessels. Median follow-up was 5 years (range, 3 to 7 years). Nine patients did not present with relapse of the ascites or protein-losing enteropathy, and six patients showed persistence of a small quantity of ascitic fluid with no protein imbalance or hypoproteinemia. Eight patients underwent postoperative lymphoscintigraphy, which confirmed an improvement in lymph flow and a decrease in lymph reflux.

#### GENERAL REMARKS

From the immunological point of view, it is important to avoid the leakage of immunoglobulins and lymphocytes into the ascitic fluid in order to maintain immunologic competence. Lymph in the thoracic duct contains from ~2,000 to 20,000 lymphocytes per mm<sup>3</sup>, i.e., a concentration of lymphocytes 2-10 times higher than in the blood. This lymphocytosis varies according to the number of lymph nodes, temperature, digestive phase and endocrine conditions. It is, therefore, easy to understand the importance of restoring normal drainage of the intestinal lymph circulation.

In case of an isolated picture of chyloperitoneum, it should be pointed out that, owing to the primary nature of the disease especially in children and young adults, the presence of extended cutaneous hemangiomas in the chest or the limbs – normally flat, of a cafe au lait or port wine color – may be a sign of the disease. No familial tendency has yet been confirmed for these malformations. Clearly information about the patient's medical history and a clinical examination are fundamental for diagnosis and must be conducted in a comprehensive fashion (99).

According to some authors, the definition of "acute chylous peritonitis" is not accurate, since pain is caused by the rapid swelling related to chylous leak into the peritoneal cavity rather than to direct chylous action irritating or inflaming the peritoneum. However, intraoperative findings as well as peritoneal biopsies have shown the presence of significant acute inflammation process. This finding would confirm the typical clinical picture of an acute abdomen, which, in about half of cases could initially lead to an incorrect diagnoses of "perforated gastroduodenal ulcer," "acute appendicitis," or acute "cholecystitis." These acute forms are unlikely to be complicated by septic shock. Subacute and chronic forms are more subtle, where chylous leak is slow and progressive, with practically no pain, which the patient feels rather an annoyance or burden due to abdominal distension. Distension, in turn, raises the diaphragm, with subsequent significant breathing capacity reduction and related subjective and objective symptoms. Vomiting is frequent in children.

In case of slow chylous leak, adult patients can show a

greater adjustment capacity for even for longer periods (weeks, months, even years) depending on the severity and cause of chyloperitoneum until some sort of spontaneous, probably unstable balance is reached.

In the majority of cases, malnutrition is present, with significant hypoproteinemia – specially affecting the albumin fraction – and weight loss. Respiratory problems and steatorrhea are also often present in PLE-associated forms.

The chylous nature of the effusion can be confirmed not only from its peculiar milky color, but also by chemical analysis which will show a high fat concentration (cholesterol, lipoproteins, chylomicrons). For a proper differential diagnosis, paracentesis is fundamental: this procedure allows verification of the nature of the effusion and confirmational clinical and imaging (US and CT) results. It is generally employed to confirm clinical assumptions, while laboratory tests are useful to show the presence of leukocytosis and related lymphopenia. Particularly in acute onset forms, bacteriological analysis coupled with antibiotic sensitivity is useful to implement a targeted antibiotic therapy when necessary. In our opinion, all of these patients, even those with acute onset, should not undergo operation prematurely until at least a proper diagnosis has been made as to the nature and site of the likely leak. During this period, the patient should be properly metabolically compensated through an appropriate diet with protein integration and limited lipid input confined only to medium chain triglycerides (MCT). MCTs, rather than being absorbed through intestinal chyliferous lymphatic roots, use the portal venous pathway. The addition of water-soluble vitamins (ADEKs tablet) should also be considered.

In conclusion, considering the etiopathogenesis as well as the nature and complexity of chyloperitoneum, the treatment of these difficult pictures and the outcome significantly depend on the skills of the physicians/surgeons and on the available technology and equipment. For this reason, it is highly recommended that these patients be referred to the few centers that have a specific surgical experience in the treatment of this disease.

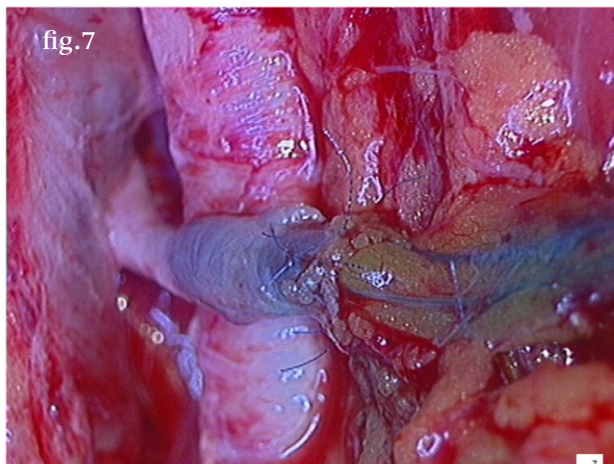
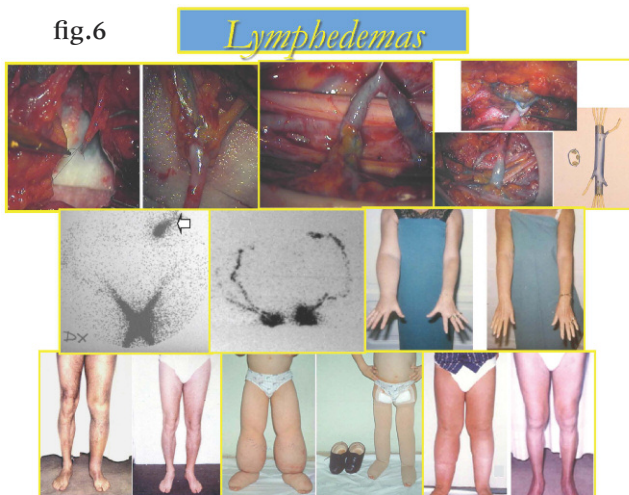
#### FRONTIERS IN LYMPHATIC SURGERY

In recent years, both primary and secondary peripheral lymphedemas are becoming better understood and more manageable problems with increased awareness and early detection (Fig.6) Nonetheless, apparent non-operative measures are aimed at minimizing morbidity without removing the cause of the underlying disturbance. Microsurgical derivative and reconstructive operations can restore lymphatic drainage, both in the short and long term, and the best results are obtained when these surgical procedures are combined with physical rehabilitative methods.

Emphasis should be placed on prevention of secondary limb lymphedemas based on an understanding of the multifactorial etiology of the disorder (100-108). Presently, it is possible to identify some preoperative



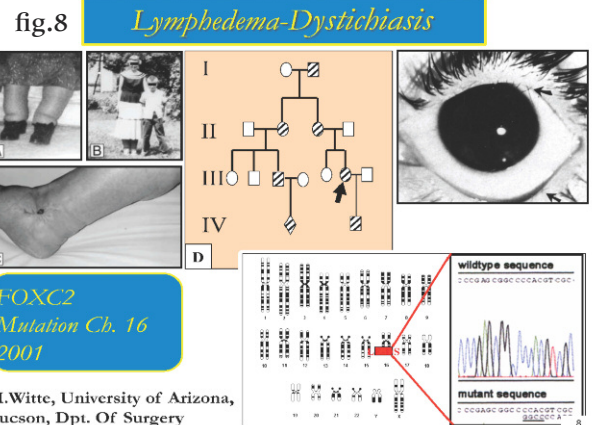
factors that distinguish women at greatest risk of developing lymphedema. By altering the operative management of the axilla (or in the future-the groin and retroperitoneum) in patients with cancer requiring operative resection and lymph nodal sampling, and without compromising the principles of cancer treatment, it may be possible to effect sequelae. It is now also possible to detect postoperative changes in the latent phase before the development of swelling. Using these methods, those in whom lymphedema is most likely to occur can be identified and early prophylactic initiation of non-operative methods should prove more effective than their implementation when swelling has become established.



The authors of the clinical experience in the prevention of secondary peripheral lymphedemas involves the use of an original diagnostic and therapeutic protocol for lymphedema prevention, which includes apart from the clinical evaluation of the patient also lymphangioscintigraphy. Lymphoscintigraphy may demonstrate the presence of pre-existing anatomic abnormalities of the lymphatic circulation predisposing to specific lymphatic circulatory disorders or document the presence of impaired lymph drainage before the clinical evidence of edema. A therapeutic preventive protocol, including non-operative measures and microsurgical operations may help specifically in avoiding the appearance of lymphedema or in treating it very early al-

lowing recovery from the lymphatic disturbance completely and definitively. Recently, we proposed the use of microsurgical lymphatic-venous anastomoses for primary surgical prevention of lymphedema due to breast cancer treatment by performing microanastomoses simultaneously with axillary lymph nodal dissection (109-110) (Fig.7).

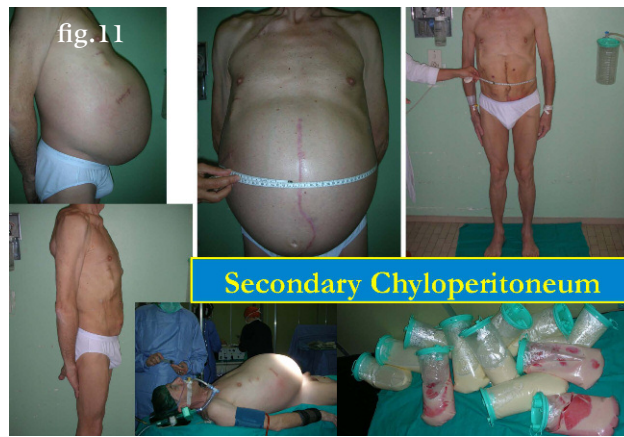Surgery exists because of the ignorance of medicine that could avoid the need for surgery. Using phenotype-genotype correlations which are under way, it may be possible to identify genetic predispositions to secondary post-surgical lymphedema development (e.g. genetic defects in lymphatic-specific growth factors/ receptors). In families with primary lymphedema where linkage or mutations are identified, testing of young clinically unaffected members permits early diagnosis and preventive management of congenital lymphedemas (111-115). Prophylactic and tailored therapeutic surgery may be based on the individual or tumor genotype laying the groundwork for "surgicogenomics" analogous to preventive surgery in familial endocrine tumors. Gene therapy aimed at stimulating new lymphatic growth or improved lymphatic function in affected limbs is also a possibility for the future. New, large families with primary lymphedema and much larger well-characterized populations with secondary lymphedema for genomewide association discovery analysis are needed for further molecular genetic insights applicable to the clinical arena (Fig.8).



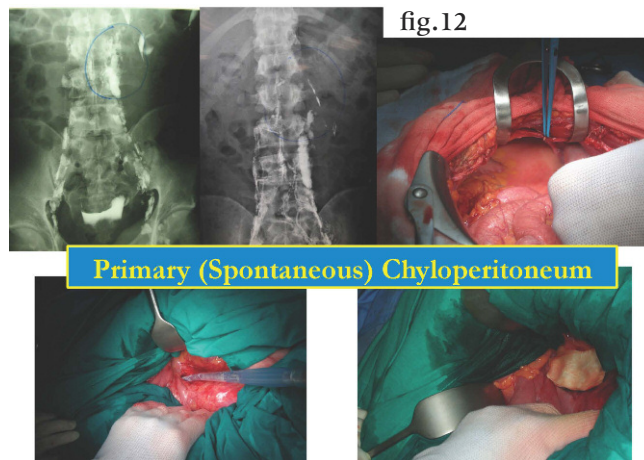
Trauma and reconstruction may long remain the province of the surgeon including the lymphatic surgeon, and the development and testing of lymphangiomodulators will need great advances, e.g. anti-lymphangiogenic agents to surpass some of the current successes in resective operations for example in massive lymphangiomas But only the future will tell what interventions will fall in and out of the future surgeon's province and purview (116) (Fig.9-10).

In summary, as medicine advances, in addition to improved control of primary and invasive cancer and of infections such as filariasis, which account for the bulk of acquired lymphedema conditions, both preventive and new options in non-operative management of lymphedema and other lymphatic disorders should emerge (Fig.11-13). These will range from prevention and

early detection of congenital disorders even during fetal life; gene therapy and protein replacement to up- or downregulate lymphatic growth, development, and tumors (lymphangiomodulators); stem cell therapy, tissue engineering and transplantation to reconstitute lymphatic channels; drugs to reduce lymph formation and accelerate lymph flow and propulsion and also to prevent or minimize the fibrosis, inflammation, immunosuppression, elastin destruction, and adipose hypertrophy characteristics of lymph stasis; and evolving lymphatic genomics and proteomics to assess risk and personalize new molecular-based therapies. Until then, guided by improved dynamic and molecular multi-modal lymphatic system imaging, surgery and surgeons will likely play an increasing role in research, prevention, and management including potential "cures" of both primary and secondary lymphatic disorders such as chylous reflux syndromes and lymphatic trauma as well as in correction, resection and/or eradication of major malformations and tumors involving the lymphatic system (116b)(Fig.14).



Secondary Chyloperitoneum



Primary (Spontaneous) Chyloperitoneum

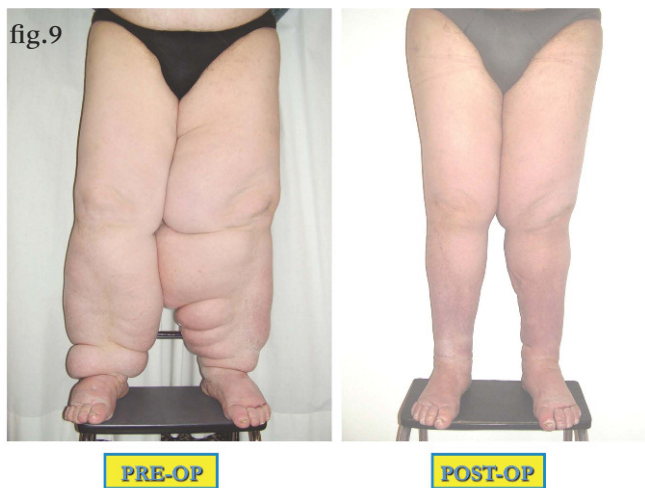
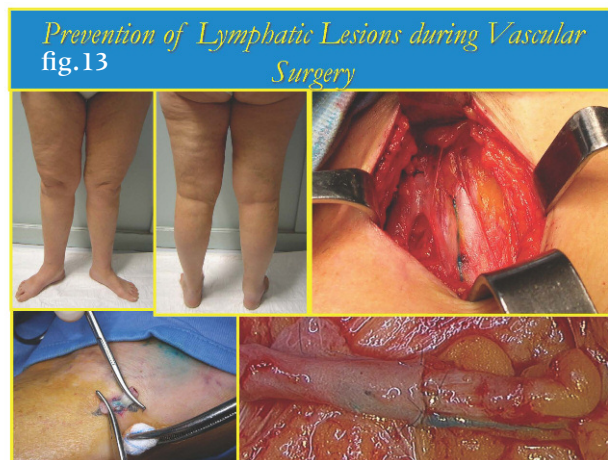
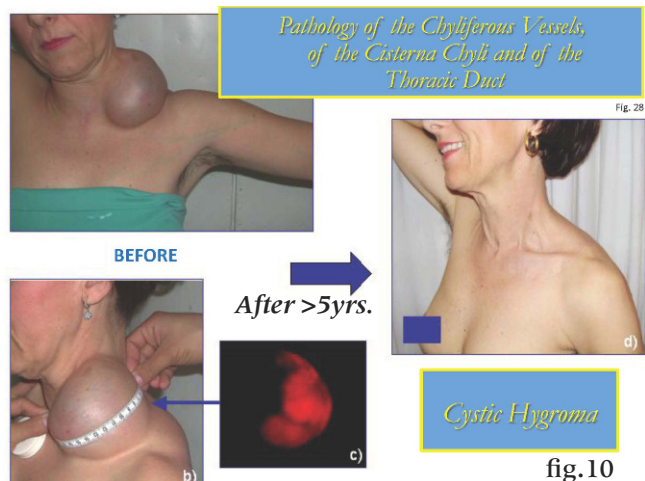fig.9



Prevention of Lymphatic Lesions during Vascular Surgery  
fig.13



Pathology of the Chyliferous Vessels, of the Cisterna Chyli and of the Thoracic Duct

Cystic Hygroma

fig.10

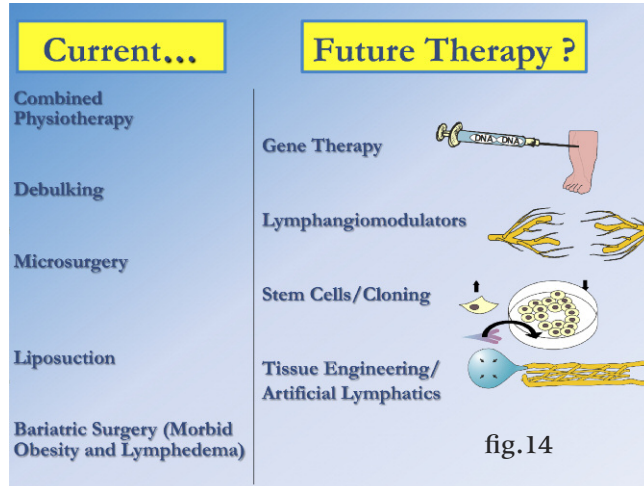


fig.14

REFERENCES

- 1.Kinmonth J.B., *The lymphatics: surgery, lymphograph and diseases of the chyle and lymph systems.* Edward Arnold, London, 1982.
- 2.Servelle M., Noguès C. *The chyliiferous vessels.* Expansion Scientifique Française, Paris, 1981.
- 3.Acconcia A. *Tecnica per la linfangiografia degli arti inferiori.* Rass. Ital. Chir. e Med., 6, 59, 1957.
- 3b. Carciati E. *La linfostasi e la patologia del dotto toraico.* Piccin, Padova, 1978.
4. Witte MH, Dellinger MT, McDonald DM, Nathanson SD, Boccardo FM, Campisi CC, Sleeman JP, Gershenwald JE. *Lymphangiogenesis and hemangiogenesis: potential targets for therapy.* J Surg Oncol 2011 May 1;103(6):489-500.
- 5.Cockett, ATK, and Goodwin, WE: *Chyluria: Attempted surgical treatment by lymphatic venous anastomosis.* J. Urol. 88:566, 1962
- 6.O'Brien, BM, Sykes, P, and Threlfall GN, et al: *Microlymphaticovenous anastomoses for obstructive lymphedema.* Plast. Reconstr. Surg. 60:197, 1977
- 7.O'Brien, B: *Microlymphatic-venous and resectional surgery in obstructive lymphoedemas.* World J. Surg. 3, 3, 1979
- 8.Degni, M: *New microsurgical technique of lymphatico-venous anastomosis for the treatment of lymphedema.* Lymphology 14:61, 1981
- 9.Degni, M: *New techniques of lymphatic-venous anastomosis for the treatment of lymphoedema.* Cardiovasc. Rivista Brasileira 10:175, 1974
- 10.Clodius, L, Pillar, NB, and Casley-Smith, JR: *The problems of lymphatic microsurgery for lymphoedema.* Lymphology 14:69, 1981
- 11.Clodius, L: *Problems of microsurgery in lymphedema.* Handchir. Mikrochir. Plast. Chir. 14:79, 1982
- 12.Huang, GK, Hu, RQ, and Liu, ZZ, et al: *Microlymphaticovenous anastomosis in the treatment of lower limb obstructive lymphedema: analysis of 91 cases.* Plast. Reconstr. Surg. 76:671, 1985
- 13.Krylov, Vs, Milanov, NO, and Abalmasov, KG, et al: *Reconstructive microsurgery in treatment of lymphoedema in extremities.* Int. Angiol. 4:171, 1985
- 14Zhu, JK, Yu, GZ, and Liu, JX, et al: *Recent advances in microlymphatic surgery in China.* Clin. Orthop. 215: 32, 1987
- 15Al Assal, F, Cordeiro, AK, and De Souza e Castro, I: *A new technique of microlympho-venous anastomoses.* Experimental study. J. Cardiovasc. Surg. 29: 552, 1988
- 16.Olszewski, W: *Recurrent bacterial dermatolymphangioadenitis (DLA) is responsible for progression of lymphoedema.* Lymphology 29 (Suppl):331, 1996
- 17.Olszewski, W: *Bacteriological Studies of skin, tissue fluid and lympho in filarial lymphedema.* Lymphology 27 (Suppl):345, 1994
- 18.Olszewski, W: *Handbook of Microsurgery.* Boca Raton, CRC Press, 1984
- 19.Olszewski, WL: *The treatment of lymphedema of the extremities with microsurgical lympho-venous anastomoses.* Int. Angiol. 7:312, 1988
- 20.Gloviczki, P, Fisher, J, and Hollier, LH, et al: *Microsurgical lymphovenous anastomosis for the treatment of lymphedema: a critical review.* J. Vasc. Surg. 7:647, 1988
- 21.Ho, LC, Lai, MF, and Yeates, M, et al: *Microlymphatic bypass in obstructive lymphoedema.* Br. J. Plast. Surg. 41:475, 1988
- 22.Baumeister, RG, and Siuda, S: *Treatment of lymphedemas by microsurgical lymphatic grafting: what is proved?* Plast Reconstr Surg. 85:64, 1990
- 23.O'Brien, BM, Hickey, MJ, and Hurley, JV, et al: *Microsurgical transfer of the greater omentum in the treatment of canine obstructive lymphoedema.* Br. J. Plast. Surg. 43:440, 1990
- 24.O'Brien, BM, Mellow, CG, and Khazanchi, RK, et al: *Long-term results after microlymphaticovenous anastomoses for the treatment of obstructive lymphedema.* Plast. Reconstr. Surg. 85:562, 1990
- 24b.Yamada, Y: *Studies on lymphatic venous anastomosis in lymphedema.* Nagaya J. Med. Sci. 32:1, 1969
- 25.Becker, C, Hidden, G, and Godart, S: *Free lymphatic transplant.* EJLRP. 2, 6:75, 1991
- 26.Trévidic, P, Marzelle, J, and Cormier, JM: *Apport de la microchirurgie au traitement des lymphoedèmes.* Editions Techniques -Encycl. Méd. Chir. (Paris-France), Techniques chirurgicales - Chirurgie vasculaire 43:3, 1994
27. Campisi C.: *Microchirurgia Applicata in Clinica Chirurgica Generale e d'Urgenza,* Utet, Torino, 1991 (monografia)
- 28.Abalmasov, KG, Egorov, YS, and Abramov YA, et al: *Evaluation of the greater omentum in the treatment of experimental lymphedema.* Lymphology 27:129, 1994
- 29.Campisi, C, and Boccardo, F: *Role of microsurgery in the management of lymphoedema.* Int. Angiol. 18:47, 1999
- 30.Campisi, C: *Lymphoedema: modern diagnostic and therapeutic aspects.* Int. Angiol. 18:14, 1999
- 31.Campisi, C, Boccardo, F, and Zilli, A, et al: *Long-term results after lymphatic-venous anastomoses for the treatment of obstructive lymphedema.* Microsurgery 21:135, 2001
- 32.Papendieck, CM: *Temas de Angiologia Pediatrica.* Buenos Aires, Editorial Medica Panamericana, 1992.
- 33.Papendieck, CM: *The big angiodysplastic syndromes in pediatrics with the participation of the lymphatic system.* Lymphology 31(Suppl):390, 1998
- 34.Dellachà, A, Fulcheri, E, Boccardo, F, Campisi C. *Post-surgical lymphedema: Iatrogenic or pre-existing disease?* Lymphology 31:562, 1998
- 35.Erickson, VS, Pearson, ML, and Garz PA, et al: *Arm edema in breast cancer patients.* J. Natl. Cancer Inst. 17:93:96, 2001
- 36.Farrar, WB. *Breast Cancer, in Cancer Surgery,* edited by RJ McKenna, GP Murphy. Philadelphia, JB Lippincott Company, 1994 p 209
- 37.Ferrandez, JC, Serin, D, and Bouges, S: *Frequency of lymphedema of the upper limb after treatment of breast cancer. Risk factors. A propos of 683 cases.* Bull. Cancer 83:989, 1996
- 38.Bellini, C, Boccardo, F, and Taddei, G, et al: *Diagnostic protocol for lymphoscintigraphy in newborns.* Lymphology 38:9, 2005
- 39.Bollinger, A, Jager, K, and Sgier F, et al: *Fluorescence microlymphography.* Circulation 64:195, 1981
- 40.Bourgeois, P, Leduc, O, and Leduc, A: *Imaging techniques in the management and prevention of posttherapeutic upper limb edemas.* Cancer, 83 (12 Suppl American): 2805, 1998
- 41.Bourgeois P, and Wolter F: *Lymphoscintigraphy demonstration of a protein loosing enteropathy.* EJLRP 18:44, 1990
- 42.Insua, EM: *Diagnostico por imagen de la patologia veno-linfatica de las extremidades.* Linfologia 3:15, 1996
- 43.Mariani, G, Campisi, C, and Taddei, G, et al: *The current role of lymphoscintigraphy in the diagnostic evaluation of patients with peripheral lymphedema.* Lymphology 31(Suppl):316, 1998
- 44.Pecking, AP, Floiras, JL, and Rouéssé, J: *Upper limb lymphedema's frequency in patients treated by conservative therapy in breast cancer.* Lymphology 29(Suppl):293, 1996
- 45.Pecking, AP, and Cluzan RV: *Assessment of lymphatic function: 15 years experience using radionuclide methods.* Lymphology 27(Suppl):301, 1994
- 46.Pecking, AP, Gougeon-Bertrand, FJ, and Floiras, JL. *Lymphoscintigraphy. Overview of its use in the lymphatic system.* Lymphology 31(Suppl):343, 1998
- 47.Witte, C, McNeill G, and Witte, M, et al: *Whole-body lymphangioscintigraphy: making the invisible easily visible,* in *Progress in Lymphology XII,* edited by N. Mitsumas, S. Uchino, S. Yabuki, Amsterdam:New York:London:Tokyo, Elsevier Science Publishers B.V., 1989 p 123
- 48.Bruna, J, Brunova, J, and Jurgova, T: *Direct lymphography as safe procedure.* Lymphology 29 (Suppl):111, 1996
- 49.Bruna, J: *Indication for lymphography in the era of new imaging methods.* Lymphology 27 (Suppl):319, 1994
- 50.Campisi, C: *Rational approach in the management of lymphedema.* Lymphology 24, 48, 1991
- 51.Campisi, C: *Use of autologous interposition vein graft in management of lymphedema.* Lymphology 24,71, 1991
- 52.Campisi, C: *Lymphatic microsurgery: A potent weapon in the war on lymphedema.* Lymphology 28:110, 1995
- 53.Campisi, C, Boccardo, F, and Tacchella, M: *Reconstructive microsurgery of lymph vessels: The personal method of lymphatic-venous-lymphatic (LVL) interpositioned grafted shunt.* Microsurgery 16:161, 1995
- 54.Campisi, C, and Boccardo, F, and Zilli, A, et al: *The use of vein grafts in the treatment of peripheral lymphedemas: Long-term results.* Microsurgery 21:143, 2001
- 55.Campisi, C, and Boccardo, F: *Frontiers in lymphatic microsurgery.* Microsurgery 18:462, 1988
- 56.Campisi, C, and Boccardo, F: *Lymphedema and microsurgery (Invited Review).* Microsurgery 22:74, 2002
- 57.Campisi, C, and Boccardo, F: *Lymphoedema, in Vascular Surgery: Cases, Questions and Commentaries,* edited by G Geroulakos, H van Urk, RW Hobson, KD Calligaro KD, Springer, 2003 p 361
- 58.Campisi, C, Davini, D, and Bellini, C, et al: *Lymphatic microsurgery for the treatment of lymphedema.* Microsurgery 26:65, 2006
- 59.Campisi, C, Davini, D, and Bellini, C, et al: *Is there a role for microsurgery in the prevention of arm lymphedema secondary to breast cancer treatment?* Microsurgery 26:70, 2006

60. Campisi, C, Bellini, C, and Eretta, et al: *Diagnosis and management of primary chylous ascites*. *J. Vasc. Surg.* 43:1244, 2006
61. Campisi, C: *Lymphology in the training and practice of general surgeons*. *G. Chir.* 28:181, 2007
62. Campisi, C, Eretta, C, and Pertile, D, et al: *Microsurgery for treatment of peripheral lymphedema: long-term outcome and future perspectives*. *Microsurgery* 27:333, 2007
63. Casley-Smith, J: *Modern treatment for lymphoedema*. The Lymphoedema Association of Australia, Inc, Adelaide, 1994
64. Casley-Smith, JR, and Casley-Smith, Judith R: *High-Protein Edemas and the Benzo-Pyrones*. Sydney, J.B. Lippincott Company, 1986
65. Casley-Smith, JR: *Alterations of untreated lymphedema and its grades over time*. *Lymphology* 28:174, 1995
66. Chang, Ti-Sheng: *Micro-wave heating oven: progress in heating and bandage treatment of chronic lymphoedema of the extremities*, in *Progress in Lymphology*, Xth ISL Congress, Adelaide, 1985 p 168
67. Cossio, JA: *Diagnostico Y Tratamiento De Los Linfedemas*. Barcellona, Ed. Centro de Documentacio de Laboratorios Uriach, 1987
68. Cossio, JA: *Progresos en Linfologia I*. Madrid, Jarpyo Editores SA, 1987
69. Földi, E, Földi, M: *Physiothérapie Complete Décongestive*. Paris, Editions Frison-Roche, 1993
70. Földi, M: *The conservative treatment of lymphoedema and physiology and pathophysiology of the lymphatic circulation*, in *Proceedings of the 4th ISL Congress*, Tucson, Arizona, 1973
71. Földi, M: *The therapy of lymphedema*. *Europ. J. Lymphol. Relat. Probl* 14, 43:1993-1994
72. Leduc, A: *Le drainage lymphatique*, in *Théorie et Pratique*. Paris, Masson, 1980
73. Michelini, S, Campisi, C, and Cavezzi, A, et al: *Epidemiologia del linfedema*. *Auxilia-Linfologia* 1:22, 1998
74. Michelini, S, Campisi, C, and Failla A, et al: *Proposal for stadiation of phlebolymphoedema*. *Europ. J. Lymphol. Relat. Probl.* 6:I, 1995
75. Vodder, E: *La méthode Vodder - Le drainage lymphatique manuel*. *Inst. for Lymph. Drainage*, DK-2880, Bagsvaer, 1969
76. Jamal S: *Lymph nodo-venous shunt in the treatment of protein losing enteropathy and lymphedema of leg and scrotum*. *Lymphology* 40:47-48, 2007.
77. Guzman, A,, L Rossi, C Witte. S Smyth: *Traumatic injury of the thoracic duct -- Lymphology* 35: 4-14, 2002
78. Cruikshank, W: *the Anatomy of the Absorbing Vessels*. 2nd edition, London, G Nicol Pall Mall, 1790
79. Busey, SC: *Congenital Occlusion and Dilation of Lymph Channels*. New York, William Wood and Co., 1878
80. Campisi, C, Boccardo, F, and Zilli, A, et al: *Chylous reflux pathologies: diagnosis and microsurgical treatment*. *Int. Angiol.* 18:10, 1999
81. Campisi, C, Da, Rin E, and Bellini C, et al: *Pediatric lymphedema and correlated syndromes: role of microsurgery*. *Microsurgery* 28:138, 2008
82. Giampalmo, A: *Patologia delle Malformazioni Vascolari*. Società Ed. Universo, Roma, 1972
83. Jamal, S, Kumaraswami, V, and Witte, MH, et al: *Lymphatic abnormalities in microfilaraemics by lymphoscintigraphy*, in *Progress in Lymphology XIV*, edited by MH Witte, CL Witte. *Lymphology* 27(Suppl):357, 1994
84. Jamal, S: *Failure in lymphedema treatment (filarial). The patient factor*. *Lymphology* 31(Suppl):403, 1998
85. Pardini, M, Bonzano, L, and Roccatagliata L, et al: *Functional magnetic resonance evidence of cortical alterations in a case of reversible congenital lymphedema of the lower limb: a pilot study*. *Lymphology* 40:19, 2007
86. Partsch, H: *Indirect lymphography in different kinds of leg oedema*. *Lymphology: Advances in Europe*. Genova, Eicg, 95, 1989
87. Bellini, C, Boccardo, F, and Campisi, C, et al: *Pulmonary lymphangiectasia*. *Lymphology* 38:111, 2005
88. Bellini, C, Boccardo, F, and Campisi, C, et al: *Congenital pulmonary lymphangiectasia*. *Orphanet J. Rare Dis.* 30:1:43, 2006
89. Bellini, C, Boccardo, F, and Bonioli E, et al: *Lymphodynamics in the fetus and newborn*. *Lymphology* 39:110, 2006
90. Bellini, C, Hennekam, RC, and Boccardo F, et al: *Nonimmune idiopathic hydrops fetalis and congenital lymphatic dysplasia*. *Am. J. Med. Genet (Part A)*. 140:678, 2006
91. Bellini, C, Boccardo, F, and Campisi C, et al: *Lymphatic dysplasias in newborns and children: The role of lymphoscintigraphy*. *J. Pediatr.* 152:587, 2008
92. Belov, St, Loose, DA, and Weber, J: *Vascular Malformations*. *Periodica Angiologica* 16 - Einhorn, Presse Verlag, 1989
93. Rutigliani, M, Boccardo, F, and Campisi, C, et al: *Immunohistochemical studies in a hydroptic fetus with pulmonary lymphangiectasia and trisomy 21*. *Lymphology* 40:114, 2007
94. Case, TC, Witte, CL, and Witte, MH, et al: *Magnetic resonance imaging in human lymphedema: Comparison with lymphangioscintigraphy*. *Magn. Reson. Imaging* 10:549, 1992
95. Browse, N, Burnard, KG, and Mortimer, PS (eds): *Diseases of the Lymphatics*, London, Arnold Publishers, 2003
96. Boccardo, F, Bellini, C, and Eretta, C, et al: *The lymphatics in the pathophysiology of thoracic and abdominal surgical pathology: immunological consequences and the unexpected role of microsurgery*. *Microsurgery* 27:339, 2007
97. Gruwez, J: *Lymphoedema, basic mechanism, clinical problems, indications for therapy, chylous reflux*, in *Proceedings of the 4th ISL Congress*, Tucson, Arizona, 1973
98. Gruwez, JA, T Lerut, T Rahardjo, and F Van Elst: *The lymphatics in angiodysplastic syndromes*, in *Progress in Lymphology*, Proc. VIIIth Int. Congr. ISL, Florence 1979, Avicenum Czechoslovak, Medical Press, Prague, 1981
99. Gyapong, JO, Adjei, S, and Sackey, SO: *Descriptive epidemiology of lymphatic filariasis in Ghana*. *Trans. R. Soc. Trop. Med. Hyg.* 90:26, 1996
100. Leitch, AM, Meek, AG, and Smith, RA, et al: *American Cancer Society Lymphedema Workshop. Workgroup I: Treatment of the axilla with surgery and radiation – preoperative and postoperative risk assessment*. *Cancer* 83 (12 Suppl American):2877, 1998
101. Logan, V: *Incidence and prevalence of lymphoedema: A literature review*. *J. Clin. Nurs.* 4:213, 1995
102. Stanton, AW, Levick JR, and Mortimer, PS: *Current puzzles presented by postmastectomy oedema (breast cancer related lymphoedema)*. *Vasc. Med.* 1:213, 1996
103. Stewart, FW, and Treves, N: *Lymphangiosarcoma in postmastectomy lymphedema; a report of six cases in elephantiasis chirurgica*. *Cancer* 1:64, 1948
104. Stratigos, JD, Potouridon, I, and Katoulis, AC, et al: *Classic Kaposi's sarcoma in Greece: A clinico-epidemiological profile*. *Int. J. Dermatol.* 36:735, 1997
105. Suneson, BL, Lindholm, C, and Hamrin, E: *Clinical incidence of lymphoedema in breast cancer patients in Jonkoping County, Sweden*. *Eur. J. Cancer Care (Engl)* 5:7, 1996
106. Werngren-Elgstrom, M, Lidman, D: *Lymphoedema of the lower extremities after surgery and radiotherapy for cancer of the cervix*. *Scand. J. Plast. Reconstr. Surg. Hand Surg.* 28:289, 1994
107. Witte CL: *Breast cancer-an overview*. *Lymphology* 27(Suppl):397, 1994
108. Witte, CL, and Witte, MH: *Consensus and dogma*. *Lymphology* 31:98, 1998
109. Boccardo F, Casabona F, and De Cian F, et al: *Lymphedema microsurgical preventive healing approach: A new technique for primary prevention of arm lymphedema after mastectomy*. *Ann. Surg. Oncol.* 2009 Jan 13. [Epub ahead of print]
110. Casabona, F, Bogliolo, S, and Ferrero S, et al: *Axillary reverse mapping in breast cancer: A new microsurgical lymphatic-venous procedure in the prevention of arm lymphedema*. *Ann. Surg. Oncol.* 15:3318, 2008
111. Benda, K, Lebloch, D, and Bendova, M: *Prevention of primary lymphedema- Possible way*. *Lymphology* 31 (Suppl): 465, 1998
112. Witte, MH, Way, DL, and Witte, CL, et al: *Lymphangiogenesis: Mechanisms, significance and clinical implications*, in *Regulation of Angiogenesis*, edited by ID Goldberg, EM Rosen EM. Basel/Switzerland, Birkhuser Verlag, 1996 p65
113. Rosen EM. Basel /Switzerland, Birkhuser Verlag; 1996.p.65
114. Witte MH, Ohkuma M, Andrade M, Campisi C, Boccardo F. *Nature's historic gap: The 20th century of Lymphology*. *Lymphology* 2005:38:157
115. Harel, L, Amir, J, and Nussinovitch M, et al: *Lymphedema praecox seen as isolated unilateral arm involvement: case report and review of the literature*. *J. Pediatr* 130:492, 1997
116. Witte MH, Dellinger MT, McDonald DM, Nathanson SD, Boccardo FM, Campisi CC, Sleeman JP, Gershenwald JE. *Lymphangiogenesis and hemangiogenesis: potential targets for therapy*. *J Surg Oncol.* 2011 May 1;103(6):489-500. Review.
- 116b. Campisi C, Witte MH, Fulcheri E, Campisi CC, Bellini C, Villa G, Campisi CS, Santi PL, Parodi A, Murdaca G, Puppo F, Boccardo F. *General Surgery, Translational Lymphology and Lymphatic Surgery*. *Int. Angiology* 2011; 30:504-21