

# THE PROSTATE: HISTORY, MORPHOLOGY, FUNCTIONAL ANATOMY

Giandomenico Passavanti

Department of Urology, Misericordia Hospital, Grosseto, Italy

**Abstract.** In western medicine, the prostate was first described and allegedly named by Herophilus of Calcedonia. For many centuries, however, physicians focused on studying the symptoms caused by prostatic diseases. It wasn't until the 16th century that the first anatomical descriptions by Vesalius, Verheyen and the anatomical renaissance tradition were available. Thorough studies of prostatic anatomy only date back to the 19th and 20th century: Lowsley studied the glandular and stromal elements and Mc Neal later proposed to divide the prostate in zones. During the last 30-40 years descriptions of the cellular composition of the prostate have significantly improved. Basal and luminal cells have been identified in the glandular component, while fibroblasts, fibrous tissue (50%) and smooth muscle cells (40-45%) have been identified in the stromal component. In young adults, smooth muscle cells are more numerous in the peri-urethral and peripheral areas. After the age of 55-60, the stroma is found in larger quantities and it is likely that the resistance to urethral urinary transit and the consequent pathogenesis of the LUTS may be influenced by the contraction of the smooth muscle component. The glandular component produces a fluid which constitutes 30% of the ejaculate and contains numerous substances necessary for spermatozoa. The prostasomes secreted in the prostatic fluid also favour the immunoprotection of spermatozoa as well as the capacitation and adhesion of spermatozoa to the pellucid zone of the oocyte. The stroma and smooth muscle cells show intense contractile activity during ejaculation to secrete prostate fluid into the lumen of the urethra; such contractile activity is otherwise milder: other more "unstable", pace-maker-like cells do cause contractions by recruiting a limited number of cells, but they also generate a resistance to prostatic urethral transit, thus contributing to urinary continence (especially in young adults). Such mechanisms are responsible for LUTS, which are however not influenced by the severity of BPH.

**Keywords:** Prostate Physiology, Prostatic smooth muscle cells, LUTS

## MORPHOLOGY

In 1912 Oswald Lowsley published the results of a series of prostate dissections carried out on three-month-old fetuses. He identified glandular groups derived from the urogenital sinus as the precursors of the two lateral lobes and glandular elements close to the posterior urethra as the precursors of the middle part, the "middle lobe" of the prostate (12). In a further paper published in 1915 the author studied the gland focusing on age differences. Lowsley measured the Length (cranio-caudal diameter) the Width (latero-lateral diameter) and the Height (antero-posterior diameter) and recorded a progressive increase in the gland's size between the second and third decade of life, reaching an average size of 20 cc at the age of 60 (thanks to the ellipsoid formula, the precise volume has now been calculated).

Lowsley also investigated a possible connection between the bladder neck, the smooth sphincter and the prostate. Smooth muscle cells connect the neck to the prostatic urethra. In young adults, the author examined the distribution of the glandular component and the glandular ducts in relation to the utriculus and ejaculatory ducts. He detected the presence of smooth muscle tissue dispersed in the interstice between the glandular corpuscles and the glandular ducts; such tissue is however found in larger quantities in the lateral areas and extending to the anterior parts (13; 14;15). This data was later reinterpreted and a layer of smooth muscle tissue matching Lowsley's description was identified: the fibrocells are distributed longitudinally, forming a "cylinder" that wraps the urethra and connects the bladder neck, the verumontanum and the peripheral areas, as some sort of smooth pseudosphincter (12).

The modern description of prostate anatomy dates back to the late 70s and early 80s, when McNeal published several papers proposing the subdivision of the prostate in zones (14). *Fig.2b*. A careful analysis of McNeal's theory shows the natural continuity with Lowsley's studies. Such continuity is no surprise: both Lowsley and

McNeal focused on the bladder neck, the lumen of the urethra, the striated sphincter and the route of the ejaculatory ducts as main anatomical landmarks. McNeal identified the peripheral areas where the glandular cells, the smooth muscle cells and the stromal component are abundant and noticed how this is the area where prostate adenocarcinoma appears most frequently; this area roughly coincides with Lowsley's posterior area. The transition zone, smaller in young subjects, is where the adenoma develops in the elderly man; the central area is larger in the young than in the elderly and corresponds to Lowsley's anterior zone, where – in younger subjects – the glandular component is significantly lower than the stromal.

The lumen of the prostatic urethra appears collapsed and takes on a horseshoe shape at the level of the utriculus (13); here, 25-30 small ducts emit the prostate secretion into the lumen of the urethra (14;15). The structure of the prostate is based on the glandular

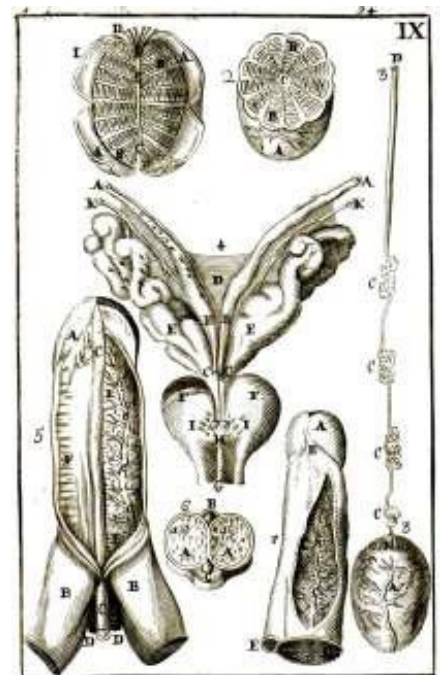


Fig - 1 - Tab IX from Philippo Verheyen "Corporis Humani Anatomiae" Berardini Gessari Lovanii 1706, the better description of the prostate in the past

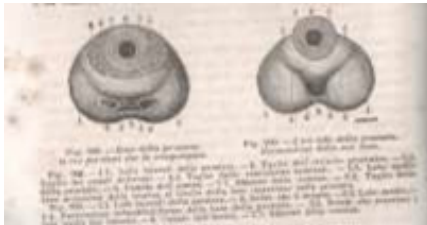


Fig. 2a - The “Sap- pey” treatise of Anatomy 1878: prostatic anatomy

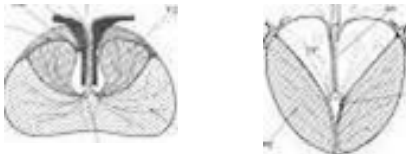


Fig. 2b - Zonal anatomy of the prostate; McNeal 1972

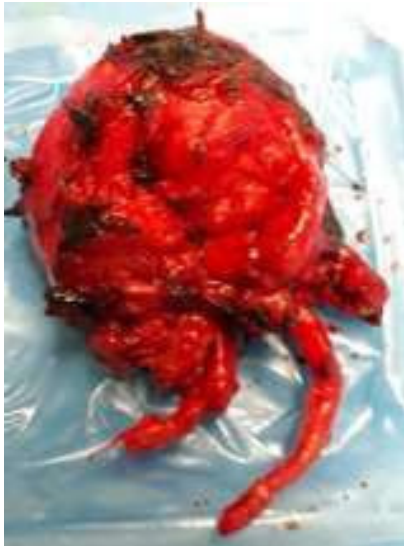

Fig. 2c - Prostate, Seminal Vesicles and Vas Deferens, dissected after Retro- pubic Radical Prosta- tectomy

in the young adult, smooth muscle fibrocells prevail in the central area, particularly near the ejaculatory ducts, while the fibroblastic component is abundant in the anterior area. *Fig.3a; Fig.3b*. The stromal component is also found in the lateral area of the peripheral zone, *Fig.4; Fig.5*, while glandular elements are abundant in medial part (16). Inside the stroma flows the vascular component; the neurovegetative nerve plexus, which leads to the corpora cavernosa (nerves erigentes), and the fibers penetrating the prostatic tissue to regulate its secretory and excretory function and, above all, the smooth muscle tone, are also found in the stroma (17). It should also be noted that BPH modifies the composition of the stroma (fibro-connective and smooth muscle) so that it consists of 50% of fibroblastic component and 45% of smooth muscular component (18).

**FUNCTIONAL ANATOMY**

It has already been mentioned that the effects of BPH on continence and minction were already known and studied in ancient times, whereas the function of the gland was not investigated until the 1850s, long after the birth of modern physiology.

Initially, it was assumed that the prostate, especially in the young adult, could “contract” around the urethra and therefore contribute to the mechanisms of continence (19), or, in pathological cases, determine obstruction. Around the same time, it was also first inferred that the ejaculate consists of both vesicular and prostate secretion. (20)

A better knowledge of this aspect was developed in the 1900s, thanks to the increasingly accurate findings regarding the composition of the prostate secretion. The presence of electrolytes and proteins

- at the time known as prostatic acid phosphatase - was explained, together with their effects on the life of the spermatozoa (21; 22). Curiously, nonetheless, physiology treatises still contained exceedingly extensive descriptions of the obstructive effects of the prostate.

With the increasing interest in andrological sciences and availability of diagnostic and research systems, knowledge on the exocrine aspect of the prostate has improved significantly, especially in the last two decades.

It is well known today that the prostate secretion, produced by glandular cells, constitutes about 30% of the

component; the epithelium it creates is made up of two types of cells, the basal epithelial and the luminal of the glandular acinus. A cytogenetic study would however result in identifying many other subclasses.

The glandular elements are immersed in a stroma consisting of fibroblasts, connective tissue and smooth muscle fibrocells (15) which makes up 65% of the prostate cellular component. As for the distribution of these cells

Fig. 3a - Smooth muscle cells in the central zone near the urethra (ac- tina marker staining) with glandular elements

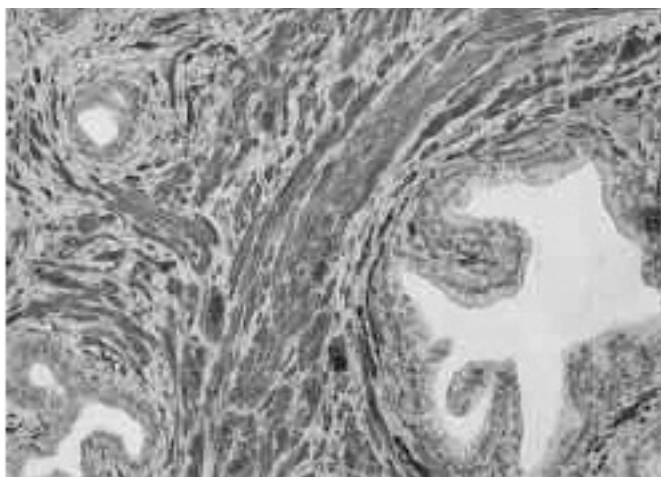
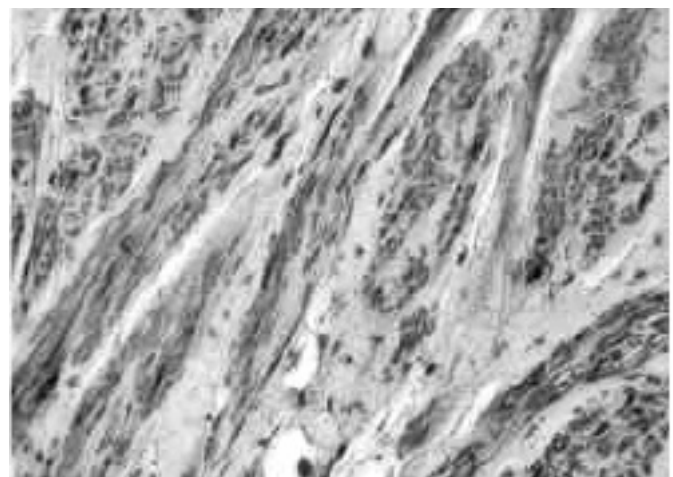


Fig. 3b - Greater magnification



ejaculated volume and its composition is characterized by the presence of Zn ++ and proteins (prostatic acid phosphatase, which hydrolyzes phosphorylcholine, releasing choline, a trophic substrate for spermatozoa); another enzyme present in the prostate secretion is PSA (Prostatic Specific Antigen), a kallikrein: this enzyme breaks up semenogelins and fibronectin, the proteins of the sperm clot. (23) This prostatic antigen was first studied by Richard Ablin in 1970 but only later given its current name (24). Most of the PSA is secreted with the ejaculate but a minimal quantity flows in the bloodstream: many different pathologies affecting the prostate cause an increase in the level of PSA in the blood (25). Prostate cells also secrete PSA precursors (proPSA) both in the ejaculate and in the blood. The prostate secretion also contains prostasomes, glandular secretory globules measuring between 40 and 500 nm in diameter. These corpuscles secrete their contents near the uterine tuba, where the oocytic fecundation takes place, after overcoming the cervico-uterine environment. Although it was initially believed that prostasomes did not adhere to the cell membrane of spermatozoa, this is now known to be possible in the uterine environment, where prostasomes serve as immunoprotectors for the spermatozoa. (26)

The aforementioned protective action is probably the reason why the prostasomes' contents improve sperm motility; these globules also participate in spermatid capacitation as well as in the lysis of the acrosome, allowing the acrosome reaction and the spermatocyte-oocyte fusion; prostasomes also act as immunomodulators to protect sperm from possible immune reactions in the uterine environment (26).

Prostasomes contain proteins (PSA, hydrolases, complement regulation factors, proteins of the Rho and Ras system), electrolytes (Zn ++, Mg ++, Ca ++), lipids (phospholipids), as well as fragments of RNA and DNA (26). Some studies have also attempted to use prostasomes as tumor markers (27).

The synthesis of the prostate secretion is modulated by the autonomic nervous system and the action of androgens. As already noted, the structural elements of the prostate gland are the secretory epithelial component and the stromal component. The latter is made up of a fibrous / fibroblastic component and a smooth fibromuscular component.

If we examine the composition of the prostate stroma we see that, in the young adult, smooth muscle fibrocells make up almost half of it. These cells, although ubiquitous in the gland, are unevenly distributed and they are arranged "in a cylinder" around the pre-montanal urethra and in continuity with the neck of the bladder; they also cluster around the glandular tubuloacinar elements; the smooth fibromuscular component is also abundant in the peripheral zone *Fig.3a; Fig.4*.

It is well known that the tone of this smooth muscle component is more intense in the older patient (> 55 aa); however, these patients show a hyperplasia of the smooth muscle component as well as of the fibrous-fibroblastic element. The tone and contractions of these smooth muscle fibrocells cause and influence LUTS (28;29).

The contraction of smooth muscles is mainly controlled by the orthosympathetic system (especially alpha1-adrenergic). (28) There are, however, other elements that interfere with the contraction, in particular Endothelin-1 and polo-like kinase 1, which does seem to act on the serine-threonine system and interferes with the cellular production of actin (29).

On a more strictly functional level, before the ejaculation, the smooth muscles' contractions intensify, recruiting a large number of fibrocells, to allow the glandular secretion to be squeezed towards the prostatic urethra through the 25-30 conduits that carry the secretion (17). The contractility of these fibers mainly depends on the alpha-1 adrenergic tone, but there are more unstable cellular elements that function as "pace-makers" and trigger contractions that spread to the other cellular elements (30). In rest conditions, however, the activity of smooth muscle cells is not completely blocked: a minimal tone is always present, although significantly less intense than in the active phase; activator cells show a lower action potential and the contractions propagate to a limited number of other cells (30).

This basic tone inevitably influences the resistance to urinary transit at the level of the prostatic urethra. In the young adult this plays an important though not decisive role, contributing to urinary containment capacity. In older patients with LUTS, this tone, caused by a higher number of smooth muscle cells and by their greater contractile recruitment, is stiffer and influences the very obstructive symptoms (29).

Fig. 4 - Smooth muscle cells in periferic zone (actina marker staining)

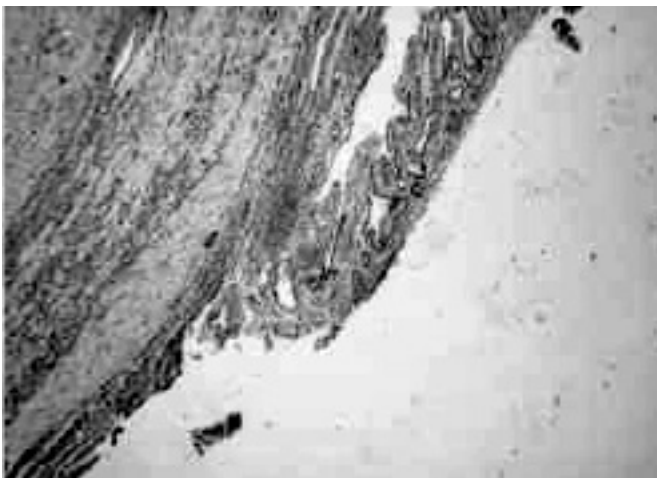
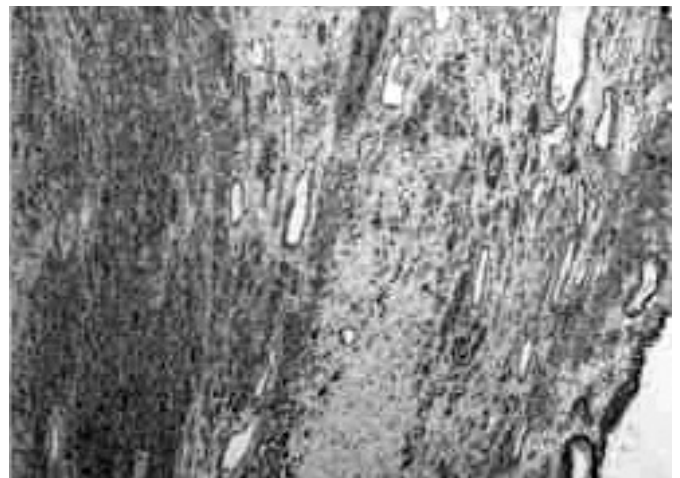


Fig. 5 - In the periphery of the gland, the glandular epithelium is more rarefied to make room for the stromal component (actina marker staining)



## DISCUSSION AND CONCLUSIONS

In short, two are the main functions of the prostate: regulating the composition and volume of the ejaculate, with the related implications on trophism and sperm function; controlling the cycle of continence/miction, through adjustments in the resistance to urinary transit at the level of the prostatic urethra; this latter function is also closely connected to the functioning of the bladder neck. In patients with LUTS, this smooth muscle component has a stronger impact on the tone of the bladder neck and the prostatic urethra, making obstructive symptoms more likely. Further evidence of the role of the prostate in urinary continence is that lesions of nerve fibers in the upper-pelvic and hypogastric plexus affect the tone of the cervico-prostatic smooth muscle and favour the onset of stress incontinence after RP interventions (31). The widening of anatomical and functional knowledge of the prostate through history has always been closely connected to the study of its pathological dysfunctions.

This relatively new interpretation allows a more thorough knowledge of the anatomy and functioning of the organ, together with a better understanding of the symptoms and explains the mechanisms that generate significant obstructive disorders: it is not indeed rare that small anatomical alterations cause severe symptoms and vice versa.

On the grounds of what has been said, when studying the cycle of continence and miction it is advisable to consider all the factors involved, including the role of the prostate gland.

## BIBLIOGRAPHY

1. Raymond G, Rognon L.M. *Historique de l'hyperplasie benigne de la prostate*. Ann Urol 26 (3): 167, 1992.
2. Bloom DA, Mc Guire EJ and Lapidus J. *A brief history of urethra catheterization*" J. Urol 151:317, 1994.
3. Tabanelli M. *Un chirurgo italiano del 1200: Bruno da Longobucco*. Leo S. Olschki, Firenze 1970
4. Paré A. *Dix livres de la chirurgie*. Livre IX Jean Le Royer Paris 1564 (anastatica)
5. Vesalii A. *De Humani Corporis Fabrica libri septem*. Libro V Johannes Oporinus Basileae 1543 (anastatica)
6. du Laurens A. *Historia anatomica Humani corporis*. Libro VI Janetus Mettayer paris 1600 (anastatica)
7. Realdi Colombi "De re anatomica Libri XV" Libro IX Nicolai Bevilacqua Ventiis 1559 (anastatica)
8. Eustachii B. *Tabulae anatomiche*. Tav .XII R<sup>e</sup>G Wetstenios Amstelaedami 1722 (anastatica)
9. Suy R, Verheyen P. (1648-1710) and his *Corporis Humani Anatomiae Acta Chir Belg* 107: 343, 2007.
10. Verheyen P. *Corporis Humani Anatomiae*. Tab VIII e IX Berardini Gessari Lovanii 1706 (anastatica)
11. Sappey MPC. *Trattato di Anatomia Descrittiva*" Vol. 4 pag 679 Enrico detken Editore Napoli 1882
12. La Taya A, Franco O, Hayward SW. *Review of prostate anatomy and embriology and the etiology of BPH*. Urol Clin North Am (4383):279, 2016.
13. Lowsley OS. *The prostatae gland in old age*. Ann Surg 62(6):716, 1915
14. McNeal JE. *The prostate and prostatic urethra: a morphologic synthesis*. J.Urol 107:1008, 1972.
15. Henry GH, Malewska A, Joseph DB, Malladi VS, Lee J, Torrealba J, Mauck RJ, Gahan JC, Raj GV, Roehrborn CG, Hon GC, MacConmara MP, Reese JC, Hutchinson RC, Vezina CM, Strand DW. *A Cellular Anatomy of the Normal Adult Human Prostate*

and Prostatic Urethra. Cell Rep. 25(12):3530-3542, 2018.

16. Chaill D, Raychaudury B. *Pelvic fasciae in urology*. Ann R. Coll. Surg Engl 90:633, 2008.
17. Emanuele Belgrano et al. "Fisiologia dell'eiaculazione" pag.43, in "I disturbi dell'eiaculazione" EDIMES Pavia 1995.
18. Park H, Park S, Kim KH, Cho MS, Sung SH, Ro JY. *Stromal nodules in benign prostatic hyperplasia: morphologic and immunohistochemical characteristics*. Prostate 74(14):1433-43, 2014.
19. Verde S e Biondi D. *Trattato di Fisiologia normale*. Pag.604 Leonardo Vallardi Editore Napoli 1881
20. Hyrtl G. *Istituzione di anatomia dell'Uomo*. pag 616 Vincenzo Pasquale editore Napoli 1883
21. Spadolini I. *Fisiologia Umana*. Vol.II pag.1291 UTET 1954
22. Hussey BA. *Fisiologia Umana*. pag 733. Il Pensiero Scientifico Editore Roma 1973
23. Aloisi AM, Passavanti G. *Apparato genitale maschile e femminile*. pag 800. In Francesca Grassi et al. "Fisiologia Umana" Poletto editore Milano 2015
24. Ablin RJ, Soanes WA, Bronson P, Witebsky E. *Precipitating antigens of the normal human prostate*. J Reprod Fertil. 22(3):573-4, 1970.
25. Scalken JA. *New developments in the molecular pathology of prostate cancer*. pag.37 In Gerald Andriole and Manfred Wirth "Prostate cancer" SIU 2011
26. Ronquist G. cap.9: "Prostasomes: Their characterization: Implications for human reproduction" pag 191, in R. Bronson "The male role in pregnancy loss and embryo implantation failure" Sprinegr Int Pub. Switzerland 2015
27. Zijlstra C, Stoorvogel W. *Prostasomes as a source of diagnostic biomarkers for prostate cancer*. J Clin Invest. 1:126(4):1144-51, 2016.
28. Mottet N, Costa P, Bali JP. *Système nerveux végétatif et physiologie prostatique. Particularités du système alpha adrénergique [Autonomic nervous system and prostatic physiology. Specific features of the alpha-adrenergic system]*. Prog Urol. 9(1):26-36, 1999.
29. Hennenberg M, Kuppermann P, Yu Q, Herlemann A, Tamalunas A, Wang Y, Rutz B, Ciotkowska A, Strittmatter F, Stief CG, Gratzke C. *Inhibition of Prostate Smooth Muscle Contraction by Inhibitors of Polo-Like Kinases*. Front Physiol. 15; 9:734, 2018.
30. Chakrabarty B, Lee S, Exintaris B. *Generation and Regulation of Spontaneous Contractions in the Prostate*. Adv Exp Med Biol. 1124:195-215, 2019.
31. Hehemann M, Choe S, Kalmanek E, Harrington D, Stupp SI, McVary KT, Podlasek CA. *Pelvic and hypogastric nerves are injured in a rat prostatectomy model, contributing to development of stress urinary incontinence*. Sci Rep. 6:8(1):16432, 2018

Acknowledgements: We would like to thank Dr. Marie Lousie Palmeri, Dr. Michela Stumpo and Dr. Armando Rossi for the collaboration in the production and interpretation of the microscopic images